

## INTRAOSSIOUS INFUSION

*Eric Vreede, Anamaria Bulatovic, Peter Rosseel, and Xavier Lassalle, Medecins Sans Frontieres, France.*

### Key Points

- Intraosseous infusion is a temporary emergency measure
- Indicated in life-threatening situations when intravenous access fails (3 attempts or >90 seconds)
- Use the anteromedial aspect of the tibia
- Insert pointing caudal to avoid the epiphyseal growth plate
- Use an aseptic technique
- Crystalloids, colloids, blood products and drugs can be infused
- Remove as soon as the child has been resuscitated and intravenous access has been established

### Introduction

The technique of intraosseous infusion was first described in humans in 1934 and it became increasingly popular in the 1940s. In recent years it has regained popularity especially in paediatric resuscitation. Unfortunately many doctors do not know this technique or do not employ it. However, intraosseous infusion is one of the quickest ways to establish access for the rapid infusion of fluids, drugs and blood products in emergency situations as well as for resuscitation. In many countries children are the victims of war trauma, road traffic accidents or severe dehydration and need good intravenous access, this technique can be life-saving. In these situations peripheral venous access can be difficult to obtain and alternatives such as central venous access can be difficult and/or dangerous.

### Introduction to the technique

The marrow cavity is in continuity with the venous circulation and can therefore be used to infuse fluids and drugs, and to take blood samples for crossmatch, for example. The procedure must be performed under sterile conditions to avoid causing osteomyelitis. It is also recommended to limit the duration of the use of intraosseous infusion to a few hours until intravenous access is achieved. It is thus a temporary emergency measure. In experienced hands intraosseous access can be established within 1 minute.

It has been shown that the onset of action and drug levels during cardiopulmonary resuscitation using the intraosseous route are similar to those given intravenously.

### Indications

Placement of an intraosseous needle is indicated when vascular access is needed in life-threatening situations in

babies, infants and children under the age of six years. It is indicated when attempts at venous access fail (three attempts or 90 seconds) or in cases where it is likely to fail and speed is of the essence. Although principally advocated for use in young children, it has been successfully used in older children where the iliac crest may also be used.

### Contra-indications

- Femoral fracture on the ipsilateral side
- Do not use fractured bones
- Do not use bones with osteomyelitis

### Equipment

1. Skin disinfectant
2. Local anaesthetic
3. 5 ml syringe
4. 50ml syringe
5. Intraosseous infusion needle or Jamshidi bone marrow needle. There are different needle sizes; 14, 16 and 18G. The 14 and 16G are usually used for children older than 18 months. However any size can be used for all ages.

It is possible but not ideal to use a 16 – 20G butterfly needle, spinal needle or even hypodermic needle. The chance that the needle gets blocked with bone marrow however, is much increased when not using a needle with a trochar.

### Site

The best site to use is the flat anteromedial aspect of the tibia. The anterior aspect of the femur and the superior

iliac crest can also be used. The tibia is preferred since the anteromedial aspect of the bone lies just under the skin and can easily be identified. Avoid bones with osteomyelitis or fractures and do not use the tibia if the femur is fractured on the same side.

### Technique

1. Palpate the tibial tuberosity. The site for cannulation lies 1 - 3cm below this tuberosity on the anteromedial surface of the tibia.
2. Use sterile gloves and an aseptic technique and a sterile needle.
3. Clean the skin. Placing a bone marrow needle without using a sterile technique obviously increases the chance of osteomyelitis and cellulitis.
4. Inject a small amount of local anaesthetic in the skin and continue to infiltrate down to the periosteum. When the child is unconscious it is not necessary to use local infiltration.
5. Flex the knee and put a sandbag as support behind the knee.
6. Hold the limb firmly above the site of insertion, usually at the level of the knee. Avoid putting your hand behind the site of insertion to avoid accidentally injuring your own hand.

7. Insert the intraosseous needle at 90 degrees to the skin (perpendicular) and slightly caudal (towards the foot) to avoid the epiphyseal growth plate.
8. Advance the needle using a drilling motion until a 'give' is felt – this occurs when the needle penetrates the cortex of the bone. Stop inserting further.
9. Remove the trochar. Confirm correct position by aspirating blood using the 5ml syringe. If no blood can be aspirated the needle may be blocked with marrow. To unblock the needle, slowly syringe in 10 ml of saline. Check that the limb does not swell up and that there is no increase in resistance.
10. If the tests are unsuccessful remove the needle and try the other leg.
11. Secure the needle in place with sterile gauze and strapping.

Correct placement is further confirmed by the following:

- A sudden loss of resistance on entering the marrow cavity (less obvious in infants who have soft bones).
- The needle remains upright without support (because infants have softer bones, the needle will not stand as firmly upright as in older children).
- Fluid flows freely through the needle without swelling of the subcutaneous tissue.

### Complications

Important complications are tibial fracture especially in neonates, compartment syndrome, osteomyelitis and skin necrosis. When an aseptic technique is used, the incidence of osteomyelitis is less than 1%. Microscopic pulmonary fat and marrow emboli do not seem to be a clinical problem. Provided the correct technique is employed there does not seem to be any long-term effects on bone growth.

### Infusion

Fluid can be infused under gentle pressure, manually by using a 50ml syringe or by inflating a blood-pressure cuff around the infusion bag. Crystalloids, blood products and drugs can be infused using this technique.

The intraosseous route should be replaced as soon as a normal vein can be cannulated and certainly within a few hours. The longer the period of use the greater the risk of complications.

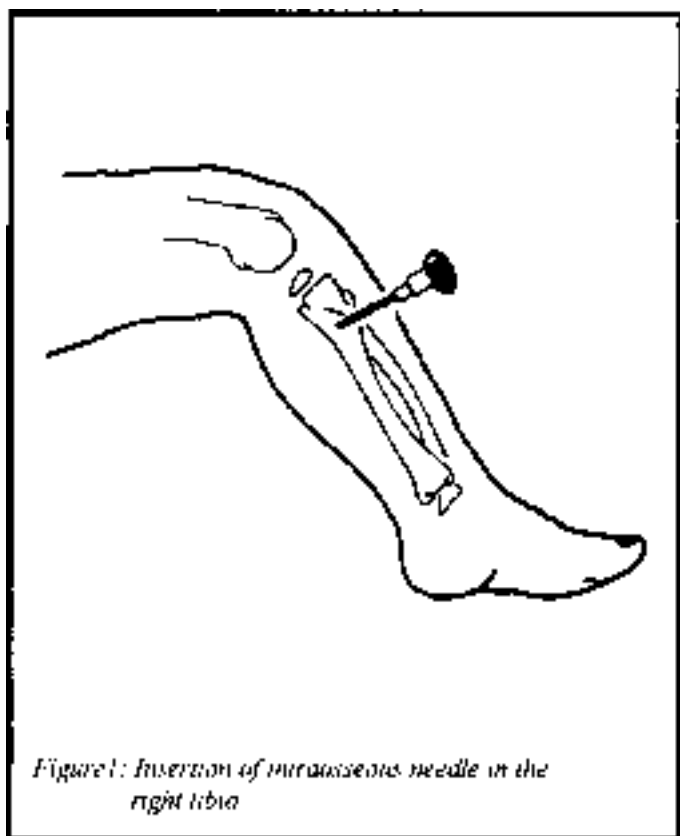


Figure 1: Insertion of intraosseous needle in the right tibia

## Conclusion

In emergencies rapid intravenous access in children may be difficult to achieve. Intraosseous access is an easy, safe and life-saving alternative.

### References

1. Chameides L, Hazinski MF, Eds. Textbook of Pediatric Advanced Life Support. 1994; 5-5 to 5-7
2. Brickman KR, Krupp K, Rega P, Alexander J, Guinness M. Typing and screening of blood from intraosseous access. *Annals of Emergency Medicine* 1992;21:414-7
3. Sawyer RW, Bodai BI, Blaisdell FW, McCourt MM. The current status of intraosseous infusion. *Journal of American College of Surgeons* 1994;179:353-60
4. Claudet I, Fries F, Bloom MC, Lelong-Tissier MC. Etude retrospective de 32 cas de perfusion intraosseus. *Archives of Paediatrics* 1999;6:566-9
5. Nafiu OO, Olumese PE, Gbadegesin RA, Osinusi K. Intraosseous infusion in an emergency situation: a case report. *Annals of Tropical Paediatrics* 1997;17:175-7

*The authors are members of the international medical aid organisation Médecins Sans Frontières (MSF).*

*Eric Vreede, Consultant Anaesthetist in London, anaesthetic advisor MSF Holland*

*Anamaria Bulatovic, attending Pediatrician in Baltimore, President of MSF USA*

*Peter Rosseel, Anaesthesiologist in Breda (Holland), Consultant Anaesthesiologist MSF Belgium*

*Xavier Lassalle, CRNA in Paris, anaesthetic advisor MSF France*