

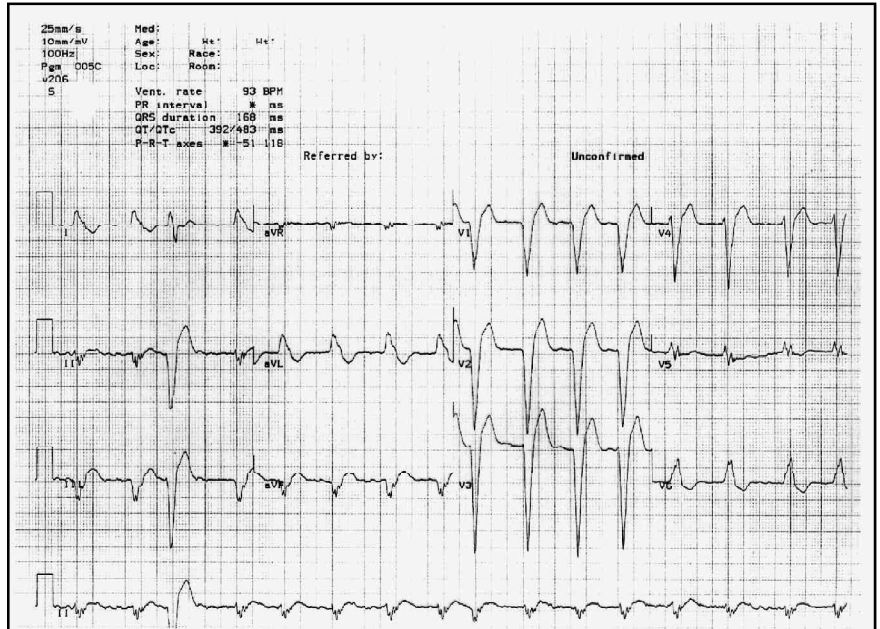
SELF-ASSESSMENT QUESTIONS

Question 1:

An 11 month-old baby is brought to the emergency department. She has been completely well until a sudden bout of coughing while playing on the floor. Her parents report that in the intervening four hours she has been unhappy and refusing to eat or drink. On examination she is found to be irritable but afebrile and not cyanosed. She is not in any respiratory distress but a soft inspiratory stridor is audible and she is drooling saliva. Examination of the rest of the respiratory system and the cardiovascular system is unremarkable. A chest X-ray is performed (shown).

- A. What is the diagnosis?
- B. How should this child be managed?

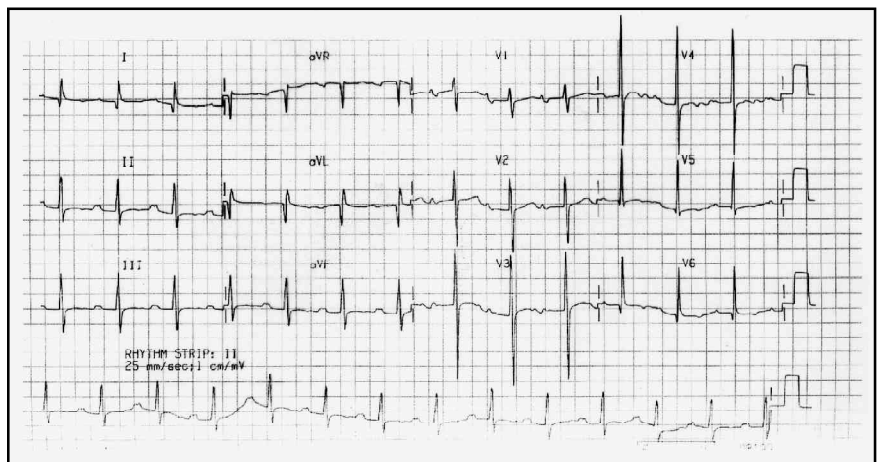
1



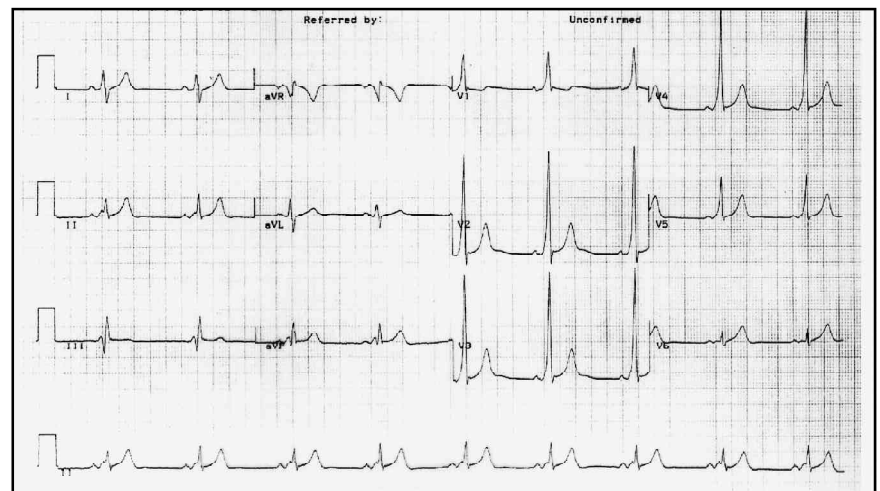
Question 2:

Interpret the following 3 electro-cardiograms.

2



3



Answers:

1a. Extrathoracic intratracheal foreign body

The sudden onset of cough and stridor in a previously well child of this age with no symptoms or signs of infection or allergic reaction make an inhaled foreign body the likely diagnosis. This is confirmed on the chest X-ray. A child with croup, epiglottitis or laryngeal oedema should not be sent for radiological investigation as this is unhelpful and dangerous. Both the diagnosis and the assessment of the severity of these cases are clinical. They were not considered likely in this case and the baby's condition was such that a x-ray was possible. This yielded valuable information as it confirmed the diagnosis and the level of the obstruction. Many foreign bodies are not radio-opaque but areas of collapse or hyperinflation (due to ball-valve type effect of the foreign body) may be seen. It needs to be emphasised that any child with a foreign body in the larynx or trachea is at risk of sudden, complete airway obstruction and if, as in this case, the decision is made that an x-ray is indicated, the x-ray needs to be taken in the emergency department or the child needs to be accompanied by an anaesthetist to the radiology department.

1b. This baby needs laryngoscopy and/or bronchoscopy and removal of the foreign body under general anaesthesia. Nothing should be done to distress the baby prior to anaesthesia as this could worsen the airway obstruction. Antisialagogue premedication is useful prior to laryngoscopy and bronchoscopy as it may make the induction smoother and makes the application of topical anaesthesia easier. This should be omitted in this case as the baby has dysphagia and the parenteral route will cause distress. An experienced ENT surgeon should perform the bronchoscopy as this can be a challenging procedure and he/she should be present during induction of anaesthesia as it is possible that a surgical airway may need to be created if the airway cannot be maintained after induction of anaesthesia. All equipment must be prepared and checked in advance. A wide range of tracheal tubes with introducers and bougies and equipment for transtracheal ventilation and emergency resuscitation drugs should be available. A range of laryngoscopes and a Storz ventilating bronchoscope and forceps is the equipment usually required by the surgeon for these cases.

Anaesthesia should be induced by means of an inhalational induction with sevoflurane or halothane in 100% oxygen. This may be prolonged if the obstruction is severe. Spontaneous ventilation should be maintained and muscle relaxants should not be used. Intravenous access should be gained after induction and atropine can be given at this stage. Anaesthesia should be maintained with halothane in 100% oxygen as this has the advantage over sevoflurane that once deeply anaesthetised the mask can be removed and the airway examined/instrumented without a rapid decrease in the depth of anaesthesia. If the foreign body is in the lower respiratory tract and bronchoscopy is to be performed applying topical anaesthesia to the respiratory tract is advisable. 4mg/kg lignocaine can be used safely and it decreases the incidence of coughing, laryngospasm and breath-holding. The trachea can also be intubated with an endotracheal tube to ascertain the correct size and to assist in the sizing of the bronchoscope.

In this case the foreign body is in the trachea and there is a constant risk of complete airway obstruction if its position changes. A careful laryngoscopy should be undertaken under deep halothane anaesthesia and the situation assessed. The surgeon and the anaesthetist should then make a decision on how best to proceed. If part of the foreign body is visible above the vocal cords it should be removed with forceps. There is the potential for it to be dislodged and to fall back and totally obstruct the airway. If the foreign body is not visible above the cords, bronchoscopic evaluation and removal should be undertaken with spontaneous ventilation/assisted spontaneous ventilation. Limited application of topical anaesthesia may be possible to the larynx. Care needs to be taken when removing it that it does not fall back and totally obstruct the airway. It may sometimes be necessary in this situation, if it cannot be rapidly removed, to temporarily push it further down past the carina to establish an airway.

When performing a rigid bronchoscopy the anaesthetic T-piece is connected to the side arm of the bronchoscope. The baby breathes through the bronchoscope and its breathing can be assisted as it is a closed system. The telescope does however narrow the lumen and greatly increases the resistance to airflow. Hypoventilation, hypoxia and too light or too deep anaesthesia are all potential problems and may cause arrhythmias in the presence of halothane. Problems of this sort are particularly likely if the bronchoscope is introduced past the carina into one lung. Withdrawal of the bronchoscope into the trachea, temporary removal of the telescope, hyperventilation with oxygen and adjusting the level of anaesthesia may be necessary.

Postoperatively the baby should be kept nil by mouth until two hours after the application of the topical lignocaine and should be given humidified oxygen. If the procedure is prolonged and postoperative airway swelling is likely dexamethasone should be prescribed and stridor can be treated with nebulised adrenaline.

In this actual case the baby was anaesthetised as above and the tip of the foreign body was just visible between the vocal cords. Its widest part had lodged at the level of the cricoid cartilage with the rest of it lying in the trachea. The anaesthetist removed it at the initial laryngoscopy. There were no postoperative problems.

2a. Atrial fibrillation, left bundle branch block (QRS complex greater than 0.12 seconds and of the LBBB pattern)

2b. First degree heart block (PR interval greater than 0.2 seconds)

2c. Ventricular pre-excitation of the Wolff-Parkinson-White type

In the normal heart only the AV node can conduct atrial impulses to the ventricle. Patients with ventricular pre-excitation have an additional connection between the atria and the ventricles. Unlike the AV node, the accessory pathway does not delay conduction between the atria and the ventricles and thus during sinus rhythm ventricular activation will occur via the accessory pathway before the impulse has traversed the AV node. However, because the accessory pathway is not connected to specialised conducting tissue the rate of ventricular activation will be slow, resulting in a slurred initial portion of the QRS complex (delta wave). Once

the atrial impulse has traversed the AV node further ventricular depolarisation will be normal. During sinus rhythm, therefore, the QRS complex is a fusion of the delta wave and a normal QRS complex. The diagnosis is made if the following are present on the ECG: a short PR interval (less than 0.12 seconds), a prolonged QRS duration (greater than 0.12 seconds) and a delta wave. In the presence of WPW type pre-excitation myocardial infarction and LBBB should not be diagnosed by the non-expert and is impossible without access to previous electrocardiograms.

These patients are prone to supraventricular tachyarrhythmias. If they occur they are said to have the Wolff-Parkinson-White Syndrome. They can arise because the AV node and the accessory pathway differ in the time they take to recover after excitation and if an ectopic beat occurs during sinus rhythm this ectopic impulse may find one pathway refractory while the other is not. After conduction down the non-refractory pathway the other pathway may have recovered resulting in the impulse repeatedly circulating between the atria and the ventricles. The result is an atrioventricular re-entrant tachycardia. If the impulse travels from

the atria to the ventricles via the AV node and back to the atria via the accessory pathway as occurs in 90% of cases the tachycardia is said to be orthodromic and the QRS complexes will be normal in appearance. If the opposite occurs, the tachycardia is said to be antidromic and the QRS complexes will show pre-excitation (broad complex). Treatment is as for any supraventricular tachycardia ie. vagal stimulation and/or adenosine initially and if necessary cardioversion or intravenous medication such as verapamil, β blockers or amioderone.

During atrial fibrillation conduction to the ventricles occurs via both the AV node and the accessory pathway. Most ventricular complexes will be broad with delta waves but some may be normal. This is a dangerous situation as very rapid ventricular rates may result. As most atrial impulses reach the ventricle via the accessory pathway drugs that slow conduction through the AV node (verapamil, digoxin) will not be effective as treatment and can increase the speed of conduction in the accessory pathway. They should be avoided. Flecainide, amioderone or sotalol can be used.
