

AIDS TO TRACHEAL INTUBATION

Dr. Sasanka S. Dhara, Staff Anaesthetist, Royal Hobart Hospital, Tasmania, Australia

Using an endotracheal tube to secure a patient's airway is still the gold standard. Most routine orotracheal or nasotracheal intubations are performed with the help of a laryngoscope that has a curved or straight blade. Other adjuncts such as external laryngeal pressure, a bougie, a stylet or a pair of Magill's forceps may also be used.

Difficulties encountered during intubation can be due to a number of factors and may be difficult to predict. It is important to have a strategy prepared and to be familiar with the equipment. This will help to avoid potential morbidity or mortality from the sequelae of hypoxia and/or cardiovascular incident that may result from a failed intubation.

The anaesthetist must be familiar with the major decision making components of the difficult airway algorithm. These are as follows:

- recognition of a difficult airway
- positioning a patient for airway manipulation
- awake intubation techniques
- techniques for anaesthetised patient with a difficult airway
- techniques for the patient who cannot be ventilated or intubated
- confirming the position of the endotracheal tube
- extubation or tube change for a patient with a known difficult airway

Over the years many attempts have been made to address various factors responsible for difficult intubations and this has resulted in a number of different techniques. It is best to use affordable, safe and useful adjuncts that are best suited to your particular anaesthetic set up.

Direct laryngoscopic orotracheal intubation

Secure intravenous access, pre-oxygenate and then induce the patient. A source of oxygen and facilities for mask ventilation should be present. Unconscious patients may obstruct their airways and the mechanism for this may be:

- the relaxed soft palate falling onto the posterior pharyngeal wall
- relaxed muscles on the floor of the mouth letting the tongue fall back against the posterior pharyngeal wall
- the epiglottis getting stuck in the glottic inlet

Various devices may be used to overcome mechanical airway obstruction:

- An **oropharyngeal airway** is useful although care should always be taken when inserting it to avoid damaging the patient's teeth and oral soft tissues.

- A **nasopharyngeal airway** may be better tolerated than an oropharyngeal airway in a patient recovering from general anaesthesia because it causes less salivation and coughing. It may cause nasopharyngeal bleeding on insertion.

- The **Laryngeal Mask Airway (LMA)** can be used as a primary airway in an unconscious patient and it has also been used for emergency airway management although it does not protect the airway from regurgitated stomach contents.

- The **Cuffed Oropharyngeal Airway (COPA)** is a modified oral airway with an inflatable cuff mounted at its distal end.

- **Laryngeal Tube (LT)** is a short S-shaped tube with two cuffs: a small oesophageal cuff at the distal end that blocks entry into the oesophagus and reduces the likelihood of gastric inflation, and a large pharyngeal cuff to stabilise the tube and to block the naso- and oropharynx. There is a ventilation hole between the two cuffs that aligns with the larynx. The laryngeal tube is blindly inserted and positioned by the 'teeth marks' on the stem of the tube. It has been used as an alternative to ventilation with a facemask or LMA.

When ready to intubate, have the following ready:

- A pillow or a padded ring to elevate the head by 8-10 cm. This manoeuvre helps to align the laryngeal and pharyngeal axes. For obese and pregnant patients, a pillow under the shoulder blades to elevate the upper thoracic spine may help with better visualisation of the larynx during direct laryngoscopy.
- A working laryngoscope handle with a choice of two blades.
- Reliable suction.
- Endotracheal tube with another that is half a size smaller. A syringe to inflate the cuff.
- Intubating stylet and Eschmann gum elastic bougie
- A pair of Magills forceps.
- Local anaesthetic spray and lubricant gel.
- Tape or tie to fix the endotracheal tube.
- Stethoscope to confirm the correct positioning of the endotracheal tube.
- Throat pack when the surgical operation involves areas such as the nasal passage, mouth, tongue and pharynx.
- Routine patient monitors.
- An assistant to help with intubation. In addition to passing the laryngoscope, the endotracheal tube or the suction, the assistant may have to help with the application of external laryngeal pressure or retraction of right angle of mouth for better visualisation of the laryngeal inlet. External laryngeal pressure is applied on to thyroid cartilage in a backward, upward direction

and can help the operator to visualise the glottis. It is not the same as cricoid pressure.

Some of the common causes of difficult direct laryngoscopy are:

- Improper positioning. Too much neck extension will result in difficulty in finding the laryngeal inlet while too much flexion will make it difficult to introduce the laryngoscope into the mouth.
- Insufficient muscle relaxation.
- Positioning of the laryngoscope blade. No tongue should be visible on the right side of the blade.
- Identification of structures. Finding the epiglottis is the key to the laryngeal inlet.
- The position of the tip of the blade. If the tip is not placed far enough into the vallecula, the view of the larynx will be closer to a grade 3 view and if it is too far into the oesophagus, the whole larynx will be missed (a common problem in neonatal intubation).
- Excessive force applied during cricoid pressure will make laryngoscopy difficult.
- The best person to find the optimal external laryngeal pressure for best view of the larynx is the person performing the intubation. Ask the assistant to put their fingers in place on the larynx and then move the assistant's hand. When the best view has been obtained the assistant can then the pressure in the right place.

Adjuncts to facilitate intubation

● **Laryngoscope handles:** A short handle may help to insert the laryngoscope blade into a patient's mouth when a normal blade is awkward to use due to the presence of large breasts in an obese or pregnant patient.

● **Blades:** The most commonly used blade in adults is the Macintosh blade. Straight Miller blades are commonly used when intubating children. The polio blade was designed for intubation of patients in an "iron lung" and may still be useful today if large breasts pose a problem.

● **Adaptors:** These adjuncts have been developed to fit between the handle and the blade of a laryngoscope to change the angle between them. They may help to visualise an anterior larynx.

● **Special laryngoscopes:** A McCoy laryngoscope has a manoeuvrable tip that is controlled by the operator (Figure 1). The tip moves anteriorly and lifts up the epiglottis. It is reputed to convert the Cormack and Lehane laryngoscopic view from 3 to 2 and from 2 to 1. A rigid bronchoscope can also be used to visualise the larynx and to place an introducer that can then be used as a guide for the endotracheal tube.

● **Stylet:** A malleable metal wire covered with plastic is used to give a tracheal tube curved shape and rigidity (Figure 2). It should be used with care as it may cause airway trauma.

● **Introducer:** This is a firm guide to lead a tracheal tube into the larynx. An example of an introducer is a gum elastic bougie that has a slightly angulated tip (coude tip) (Figure 2) and a plastic exchange catheter that has a hollow lumen to deliver oxygen through it. An introducer is especially useful when only part of

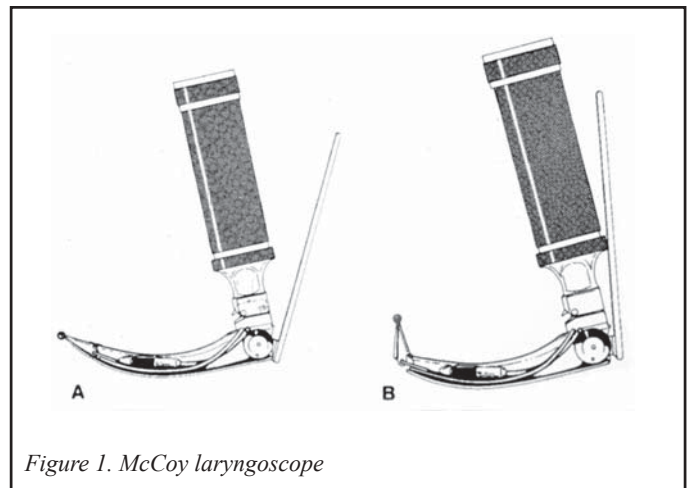


Figure 1. McCoy laryngoscope

the larynx is visualised or when only the epiglottis can be seen. The anaesthetist slides the angled tip of the introducer under the edge of the epiglottis and into the larynx where the tracheal rings can be felt. If they cannot be felt, the introducer may have entered the oesophagus. The endotracheal tube is then guided over the introducer and into the trachea whereupon the introducer is withdrawn.

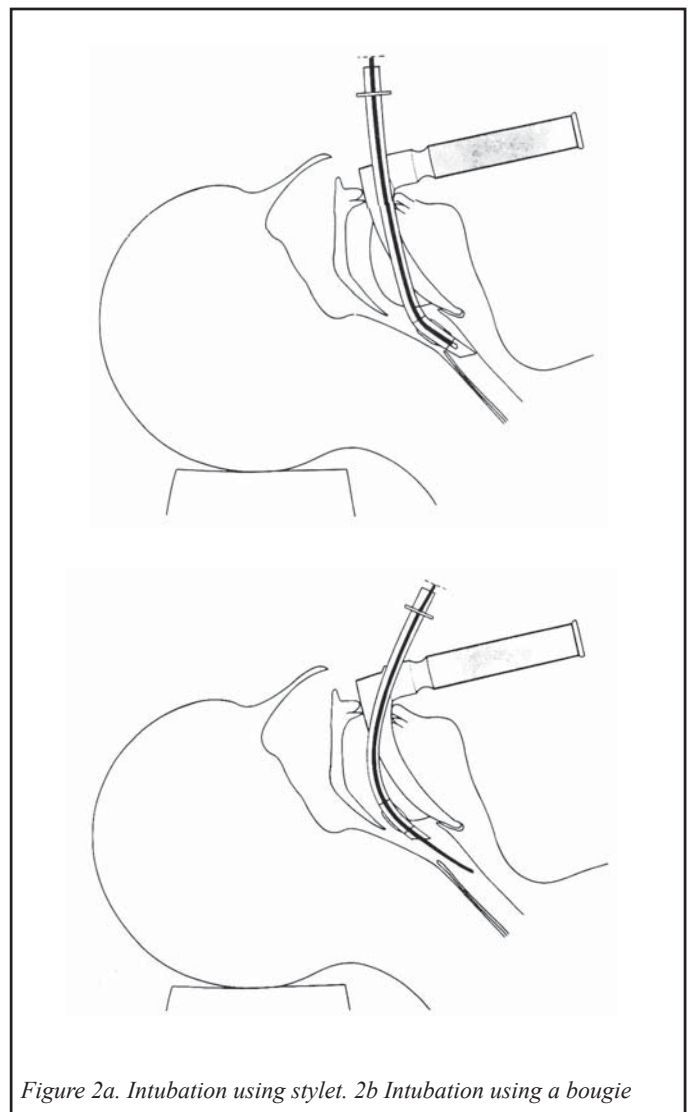


Figure 2a. Intubation using stylet. 2b Intubation using a bougie

Difficulties may be encountered when attempting to guide the endotracheal tube over the introducer in which case the following scenarios should be considered:

- Is the introducer in the airway to an adequate depth?
- Is the difference between the external diameter of the introducer and the internal diameter of the tube too great? A softened and well lubricated tube of a smaller size (typically 6, 6.5 or 7mm) will follow the guide (typically a gum elastic bougie) better as it does not “hang up” or drag the introducer out of the airway. This may happen with a larger and stiffer tracheal tube. A reinforced tube is easier to guide than a standard endotracheal tube because it is softer.
- Is the larynx too anterior? In this case, pulling the tongue forward is a useful manoeuvre to guide the tube in the right direction.
- Is the muscle relaxation sufficient?
- Is the larynx too small for the tube? In which case use a tube half a size smaller.
- Is the tube stuck at the anterior commissure? Twisting the tube on its axis anticlockwise to 90 degrees so the bevel faces posteriorly may help the tube to pass through the larynx.

Predicting a difficult intubation

Methods of predicting a potentially difficult intubation have been developed. Mallampati described an assessment with the patient sitting opposite the anaesthetist. The patient is asked to open his mouth and extend his tongue. The view obtained gives the anaesthetist an indication of the difficulty that is likely to be encountered. This system is not foolproof.

Changing an endotracheal tube

If it is necessary to change an endotracheal tube that is in place:

- Secure intravenous access and have anaesthetic and resuscitation drugs present as well as the airway adjuncts previously discussed.

- The patient should be appropriately sedated and paralysed.
- Pre-oxygenate for 3 minutes prior to changing the tube because this will give you a bit more time if the tube change proves to be difficult.
- Suction the oropharynx so that you have a clear view.
- Insert an introducer down the tube and remove the tube, leaving the introducer in situ. Then pass another tube over the introducer and remove the introducer. A smaller tube may be required if the patient has been intubated for some time as the airway may be oedematous.
- Confirm that the tube is correctly positioned by observing chest movement, auscultating the chest with a stethoscope and using capnography if available.

“Can’t ventilate, can’t intubate”

- If the patient is difficult to intubate, stop trying and return to bag and mask ventilation. If you are able to ventilate the patient then consider any adjuncts or procedures that may help you.
- If you are unable to ventilate the patient in spite of the adjuncts mentioned previously, call for help. Wake the patient up if appropriate or prepare for an emergency cricothyroidotomy.
- A 14G intravenous cannula or a cricothyroidotomy cannula is inserted through the cricothyroid membrane and oxygen under pressure is administered into the patients lungs. This is called transtracheal jet ventilation (TTJV).
- The oxygen supply is from the wall or a cylinder. It is connected to a pressure regulator and a jet actuator that is then connected to the cricothyrotomy cannula via a luer lock system (Figure 3). Remember that the oxygen is under high pressure and that the patient is at risk of barotrauma when using this method of ventilation. Adjust the driving pressure carefully and make sure that there is no obstruction to airflow on exhalation.
- Jet ventilation works mainly by bulk flow of oxygen, but a considerable volume of air is entrained from the open glottis (venturi effect).

Mallampati’s classification

Class 1	The soft palate, faucial pillars and uvula are all visible
Class 2	The soft palate and faucial pillars are visible, but the uvula is obscured by the base of the tongue
Class 3	Only the soft palate is visible

Cormack and Lehane’s classification

Grade 1	Most of the glottis is seen. No difficulty.
Grade 2	Only the posterior part of the glottis is visible. Pressure on the larynx may improve the view. Slight difficulty.
Grade 3	The epiglottis is visible, but none of the glottis can be seen. A bougie may be used. There may be severe difficulty.
Grade 4	Not even the epiglottis is visible. This situation usually arises with obvious pathology. Intubation may be impossible without special techniques.

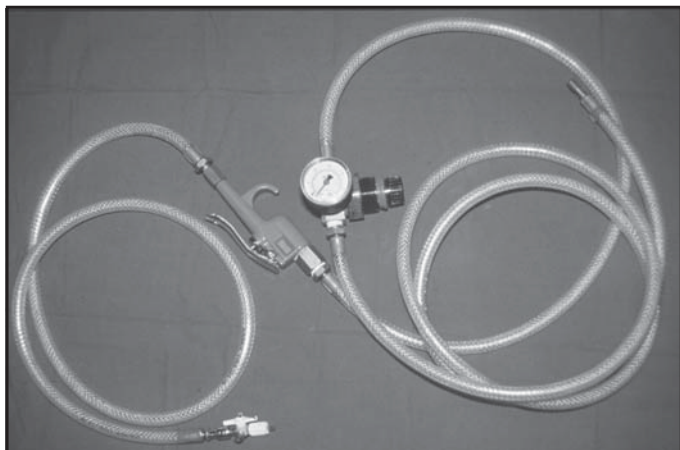


Figure 3. Assembled apparatus for jet ventilation

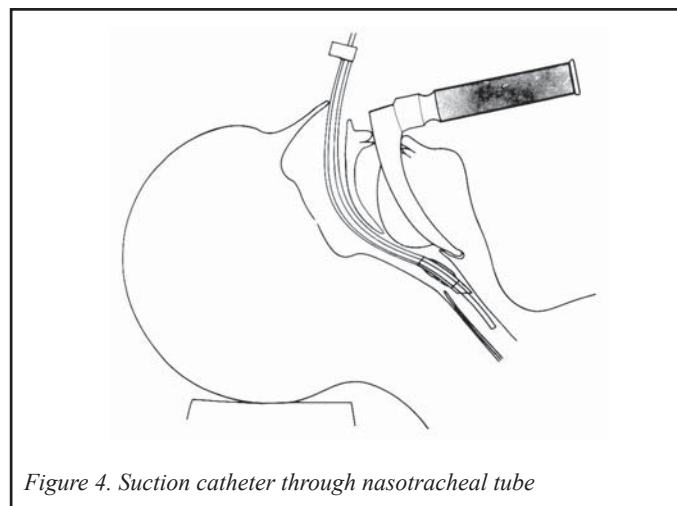


Figure 4. Suction catheter through nasotracheal tube

- Oxygenation is the main concern and this is achieved by using smaller tidal volumes, a higher respiratory rate (20-40/minute) and a longer I:E ratio (1:4).

- The emergency oxygen flush from the anaesthetic machine may be used as a source of pressurised oxygen by connecting a non-compliant tubing system to the common gas outlet with a 15 mm endotracheal tube connector. However, it should be noted that most modern machines are fitted with a safety valve to prevent overpressure of the backbar and therefore may not be suitable for this purpose.

- A 7.5 mm tracheal tube connector fitted tightly into the barrel of a 3ml luer lock syringe can accommodate a self-inflating bag on one end and the cricothyroid cannula on the other. Some oxygen can be transferred by squeezing the bag hard, but this is not 'jet ventilation'.

- These are only temporary measures.

For nasotracheal intubation using direct laryngoscopy

- Local anaesthetics can be sprayed into the nasal passage eg.cocaine 4-10% (maximum 1.5mg/kg) which has the advantage of having vasoconstrictor properties or lignocaine 2-10% (maximum 3mg/kg).

- Vasoconstrictor drugs eg.phenylephrine or pseudoephedrine nasal spray are helpful in reducing nose bleeds.

- Soften the endotracheal tube by immersing it in warm clean water.

- Insert the endotracheal into a nostril at an angle perpendicular to the face and exert gentle pressure until the tube is visualised at the back of the oropharynx. Guide the tube into the larynx using a pair of Magill's forceps if necessary. Rotating the bevel of the endotracheal tube so that it faces posteriorly allows smoother passage of the tip across the laryngeal inlet.

For emergency intubation

- A rapid sequence induction (RSI) is always performed in emergency situations, when a patient is not starved or when reflux is present. A rapid sequence induction consists of preoxygenation for 3 minutes, intravenous administration of a predetermined dose

of an induction agent eg.3 - 4mg/kg of thiopentone and a rapidly acting muscle relaxant such as suxamethonium 1-1.5mg/kg.

- Cricoid pressure is applied by an anaesthetic assistant as soon as the patient loses consciousness. The pressure applied on the cricoid ring occludes the oesophagus against the body of the 6th cervical vertebra and thus prevents regurgitation of stomach contents up into the oropharynx.

- The assistant's hand applying cricoid pressure may obstruct the introduction of the laryngoscope into the mouth. It requires a careful sideways insertion of the blade into the mouth. A laryngoscope with short handle is useful in this situation.

- The cricoid pressure is taken off only after confirmation of correct placement of endotracheal tube with the cuff inflated.

Awake intubation

Indications for awake intubation include:

- Upper airway obstruction

- A known or suspected difficult intubation

- Patient with an unstable cervical spine fracture where any traction on the neck should be avoided

- Full stomach. This technique is used in the United States of America.

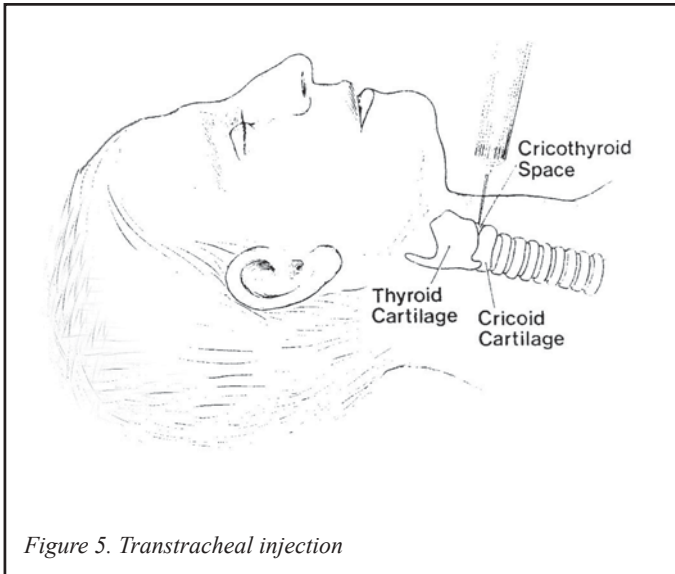
- Respiratory failure in extremis where anaesthetic induction may bring about the patient's immediate demise

The procedure for anaesthetising the airway is as follows:

- Give oxygen to the patient throughout the procedure eg.nasal prongs and ensure that all routine monitoring is in place with intravenous access secured.

- Administer a drying agent intravenously, for example atropine 400-600mcg or glycopyrrolate 200-400 mcg.

- Administer sedation to make the patient comfortable without compromising patient safety. For example, a benzodiazepine eg.midazolam 0.5-2mg along with a short acting opioid eg.fentanyl 50mcg. Although both drugs have specific antagonists available, care should be taken not to depress respiration too much.



- Local anaesthesia of the upper airway is achieved as follows: Surface analgesia is achieved with 2-4% lignocaine (maximum 3mg/kg) applied to the mouth, tongue, pharynx and nasal passages by spraying, gargling or inhaling a nebulised form. Cotton tipped pledgets soaked in the same solution may be used for analgesia of the nasal passage. A translaryngeal injection through the cricothyroid membrane provides analgesia to the area below the vocal cords. To perform this injection, identify the cricothyroid membrane and confirm that the tip of the needle is in right place by free aspiration of air in a saline-filled syringe before the injection is made (Figure 5). 2-4ml of lignocaine 4% is used because the higher concentration penetrates the mucosa more efficiently. As soon as the injection is performed the patient will cough and the needle should be withdrawn swiftly to prevent any damage.

- Have the equipment ready for the chosen technique eg. fiberoptic bronchoscope or retrograde intubation set.
- Plan for the procedure and have a rescue plan in case it fails.

Indirect laryngoscopy

- Flexible fiberoptic scope:** This instrument has changed the whole management of a difficult airway by allowing indirect visualisation of the larynx. It is made up of coated glass fibres that transmit light and images. These fibres are delicate structures and are easily damaged so the fiberoptic scope should always be handled with care. It may contain aspiration channels that can be used for suctioning secretions, insufflating oxygen or instilling local anaesthetic. One does require training in its use. Disadvantages include: poor images in the presence of bleeding or excessive secretions, initial and subsequent maintenance costs and the need for adult and paediatric sizes.

- Rigid indirect laryngoscope:** This instrument uses fibreoptics to visualise the glottis and contains a channel for the endotracheal tube. It is expensive, learning to use it takes considerable time and success rates vary.

Guided blind techniques

These techniques require the use of a physical guide to lead the endotracheal tube into the glottic inlet.

Laryngeal mask and Intubating LMA:

The laryngeal mask is probably the most important invention in anaesthesia in recent times. The LMA has been used as a conduit to reach the larynx by passing a bougie, a fiberoptic bronchoscope or sometimes a smaller tracheal tube through it. In these situations the LMA is usually left in situ until the end of the anaesthetic.

The Intubating LMA (ILMA) is a preformed, anatomically-shaped metal tube that is fitted with the usual LMA cuff (Figure 6). A specially designed tube is passed through the ILMA and into the larynx. Tube position is checked before removing the ILMA and leaving the tube in situ.

Augustine guide:

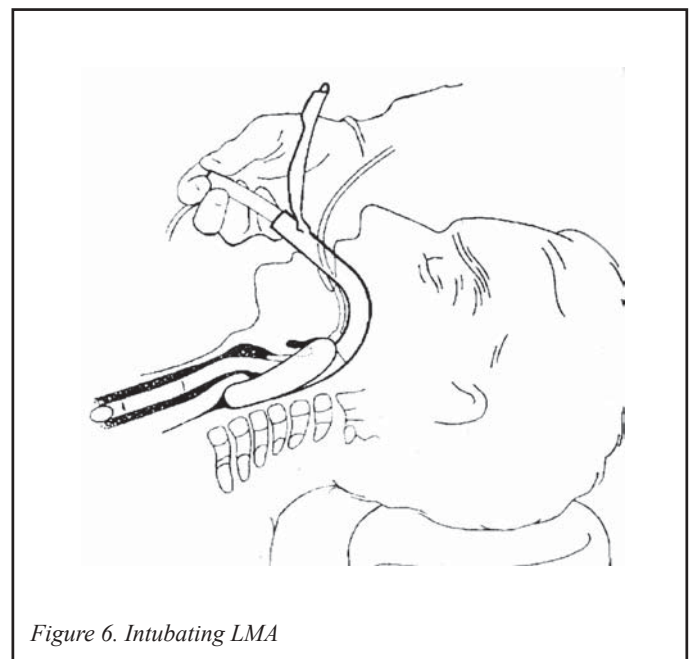
This device consists of an anatomically-shaped, disposable, plastic channelled guide with a special stylet. It combines features of pharyngeal airway, stylet, bougie and oesophageal detector device. The tube is loaded over the guide and the hollow stylet is used to find the trachea. The stylet position is confirmed by injecting air with a syringe and auscultating the stomach (oesophageal detector device). The tube is then guided over it.

In order to use it, mouth opening must be normal. It is more traumatic than normal laryngoscopy though cervical spine mobility during the procedure is minimal.

Retrograde intubation:

This technique was first reported by D.J.Waters in 1963. The basic technique consists of passing a retrograde guide through the cricothyroid membrane. This is then taken out from mouth or nose and an endotracheal tube is guided over it. There are many reports of retrograde intubation using various techniques and equipment:

- The retrograde guide may be an epidural catheter or a vascular guidewire (such as those used for insertion of a central venous



catheter) that is firmer and also the 'J' tip is less traumatic when moved inside the airway.

- A cricothyroid puncture is performed using a 16G intravenous cannula. It is important to make sure that the guide wire passes through the cannula easily. Once positioned, the cannula should be left in place, even after the retrograde guide wire has been passed through and positioned. The cricotracheal space rather than cricothyroid space has been advocated by some because it is less vascular and the depth of insertion is longer thus preventing the endotracheal tube from becoming dislodged when the retrograde guidewire is withdrawn and tracheal intubation is attempted.

- An anterograde guide such as a 14-16 FG suction catheter may be used and passed over the retrograde wire so that the endotracheal tube, when railroaded, has a better guide to follow rather than the thin and easily flexible retrograde guidewire. It is important that the anterograde guide is inserted to an adequate depth to prevent it from becoming dislodged when the patient coughs or when the retrograde guide is removed. The cough reflex is usually well suppressed from the transtracheal instillation of local anaesthetic solution. The retrograde wire is then removed and an endotracheal tube guided over the anterograde guide which is removed once correct placement has been confirmed.

- The procedure can be performed awake with appropriate application of local anaesthesia to the airway. Sedation or a small dose of induction agent will make the procedure more comfortable for the patient.

- The technique is very useful when all else has failed but it can also be used as a planned procedure. It does not require expensive equipment and with basic knowledge of anatomy, the technique can be performed easily. Contraindications are few, but include infection or tumour in the area and clotting disorders. Unlike fiberoptic bronchoscopy, the presence of blood in the airway does not hinder the procedure.

Lighted stylets or lightwands:

This method involves using a malleable stylet with a light at its tip that is placed inside the endotracheal tube. The stylet is bent to a L-shape and the patient is positioned with his head fully extended. The lightwand is passed in the midline over the tongue.

Abrupt transillumination occurs when the lighted tip passes the epiglottis enters the larynx. The stylet is then removed.

Blind techniques

The intubation is performed without a direct or indirect view of the glottis and techniques are blind nasal and tactile oral.

Blind Nasal:

This procedure may be performed in an awake patient with conscious sedation and local anaesthesia to the airway or in an anaesthetised patient breathing spontaneously. The head is positioned as for direct laryngoscopic intubation and a softened, well lubricated endotracheal tube (typically 6.5-7.5 mm in adults) is gently passed through the nostril of choice until it reaches the pharynx. Then the chin is lifted forwards and the other nostril is occluded. If the patient is awake he is asked to close his mouth and breathe deeply. Alternatively, in an anaesthetised patient, the tube is advanced slowly while listening for breath sounds at the end of the tube. Capnography is extremely useful in this situation. Breath sounds or a capnography trace indicate that the tube has passed into the trachea. Blind nasal intubation is a very useful technique because it does not need expensive equipment and can be performed anywhere.

Tactile oral (Blind oral intubation):

This technique was first reported in 1880 by William MacEwen. It is performed by palpating the larynx while guiding the tube into it.

Conclusion

In real life scenarios, these techniques may be used in combination. It will depend on the problem, the resources available and the expertise of the anaesthetist. These factors should be considered carefully so that the best technique is chosen.

Further reading

1. Fiberoptic Endoscopy and the Difficult Airway. A. Ovassapian. Second Edition, 1996. Lippincott-Raven.
2. Airway Management. Hanowell and Waldron, 1996. Lippincott-Raven.