

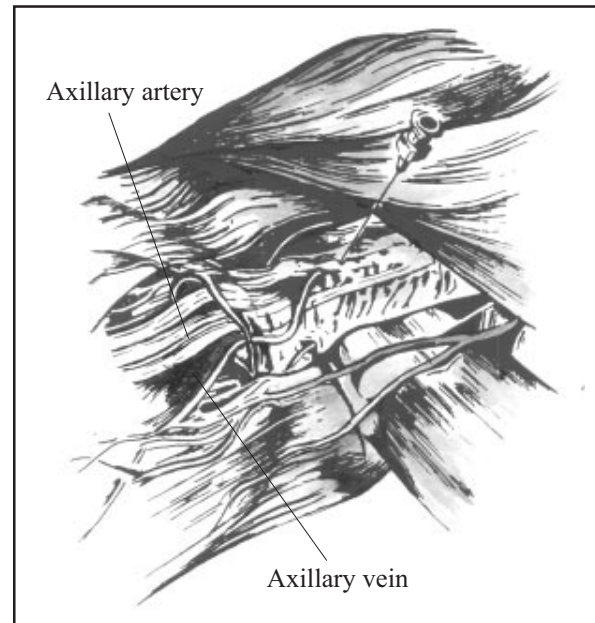
## AXILLARY BRACHIAL PLEXUS BLOCK

Dr JVB Tindinwebwa, Lecturer, Makerere University, Kampala, Uganda

An axillary block is the most commonly performed variety of brachial plexus block. The landmarks are easy to identify and it is associated with fewer complications than other approaches to the brachial plexus. The technique may be used to provide anaesthesia for a variety of surgical procedures on the hand and forearm. Although in some patients the block may extend above the elbow it does not do this reliably.

### Anatomy

The brachial plexus is derived from the cervical roots C5, C6, C7, C8 and the thoracic root T1. The plexus runs from the neck to the axilla passing between the clavicle and the first rib. In the axilla the plexus forms 3 cords which surround the axillary artery - the posterior, lateral and medial cords. The cords form the nerves to the arm - the median, ulnar, radial and the musculocutaneous nerve. The musculocutaneous nerve arises first and is often incompletely anaesthetised during an axillary block. Alongside the axillary artery runs the axillary vein. The vessels and nerves are contained in a connective tissue sheath (figure 1).



### Technique

After checking your resuscitation equipment insert an intravenous cannula in the other arm in case of emergencies. With the patient lying supine the arm is abducted to about 90 degrees, externally rotated and flexed at the elbow. A pillow should be used to ensure that the arm is in a relaxed position. Prepare the axilla using a skin sterilising solution, shaving is not necessary. Palpate the axillary artery and place a finger on it as high in the axilla as possible. Raise a skin weal superficial to the artery with 1% lignocaine. Advance the needle slowly at about 30

degrees to the skin through the weal towards the side of the artery. The needle will enter the sheath which is sometimes felt as a click. The click is best felt when a short bevelled needle is used. Correct placement in the sheath is confirmed if the needle gently pulsates indicating close proximity to the artery or if the patient complains of paraesthesia (a feeling of “pins and needles” caused by the needle touching the nerve). Aspirate to exclude intravascular placement of the needle and then inject the local anaesthetic solution. During the injection aspirate again to ensure that the needle has not changed position and entered a vessel. The injection is most conveniently performed with an extension set between the syringe and the needle. This allows the syringe to be changed without moving the needle. Some anaesthetists place a cannula into the sheath to allow further top ups of local anaesthesia. If firm pressure is placed over the sheath below the point of injection the local anaesthetic solution is encouraged towards the axilla and a better block will result.

Allow plenty of time for the block to develop (15 - 30 minutes). If it is planned to use a tourniquet during surgery some subcutaneous infiltration of local anaesthetic on the medial side of the upper arm will often improve the comfort of the patient.

### **Volumes of local anaesthetic**

This will depend on the size of the patient and the drugs available. The following doses are suggested:

*Adult:* 30-40ml  
1% lignocaine with adrenaline  
1:200,000

*Teenagers:* 40-60kg 20-25ml  
1% lignocaine with adrenaline  
1:200,000

*Children:* 25-35kg 14-20ml  
1% lignocaine with adrenaline  
1:200,000

An alternative is to use 1% prilocaine or 0.25% bupivacaine.

### **Contraindications**

Damage or disease of the brachial plexus. Sepsis in the axilla. Allergy to local anaesthetic.

### **Complications**

Arterial puncture. If this occurs slowly withdraw the needle until blood cannot be aspirated - the needle now lies in the sheath. Slowly inject the local anaesthetic. Check the needle position by aspirating twice during the injection.

Venous puncture. Withdraw the needle, put pressure over the injection site for 5 minutes and then start again.