

PERIOPERATIVE NEUROPATHIES, BLINDNESS AND POSITIONING PROBLEMS

Mark A. Warner, Professor of Anesthesiology, Mayo Clinic College of Medicine,
Rochester, Minnesota, USA
Email: mark.warner@mayo.edu

Perioperative neuropathies, vision loss, and positioning-related problems have received increasing attention from the lay press, plaintiffs' lawyers, the anesthesiology community, and clinical researchers in recent years. This review will provide an update of current findings and discuss possible mechanisms of injury for these potentially devastating problems.

UPPER EXTREMITY NEUROPATHIES

Any nerve that passes into the upper extremity may

sustain an injury or convert from an abnormal but asymptomatic state to a symptomatic state during the perioperative period. Of the major nerve structures of the upper extremity, the ulnar nerve and brachial plexus nerves are the most common to become symptomatic and lead to major disability during the perioperative period.¹⁻³

Ulnar neuropathy

Improper anesthetic care and patient malpositioning

have been implicated as causative factors in the development of ulnar neuropathies since reports by Budinger⁴ and Garrigues⁵ in the 1890s. These factors are likely to play an aetiological role for this problem in some surgical patients. Other factors, however, may contribute to the development of postoperative ulnar neuropathies. In a series of twelve inpatients with newly acquired ulnar neuropathy, Wadsworth and Williams⁶ determined that external compression of an ulnar nerve during surgery was a factor in only two patients. A prospective study at the Mayo Clinic found that medical, as well as surgical, patients develop ulnar neuropathies during inpatient and outpatient care⁷. It is clear that both surgical and medical patients may develop ulnar neuropathies during or after an episode of care.

Typically, anesthesia-related ulnar nerve injury is thought to be associated with external nerve compression or stretch caused by malpositioning during the intraoperative period. While this implication may be true for some patients, three findings suggest that other factors may contribute. First, a retrospective study has found male gender, high body mass index (≥ 38) and prolonged bedrest postoperatively to be associated with these ulnar neuropathies⁸. Of these, male gender is the factor most commonly associated with perioperative ulnar neuropathy. Various reports suggest that 70-90% of patients who develop this problem are male.^{1,2,6,8-9} Second, many patients with perioperative ulnar neuropathies have a high frequency of contralateral ulnar nerve conduction dysfunction.⁹ This finding suggests that many of these patients are likely to have asymptomatic but abnormal ulnar nerves prior to their anaesthetics, and these abnormal nerves may become symptomatic during the perioperative period. Finally, many patients do not notice or complain of ulnar nerve symptoms until more than 48 hours after their surgical procedures.^{8,9} A prospective

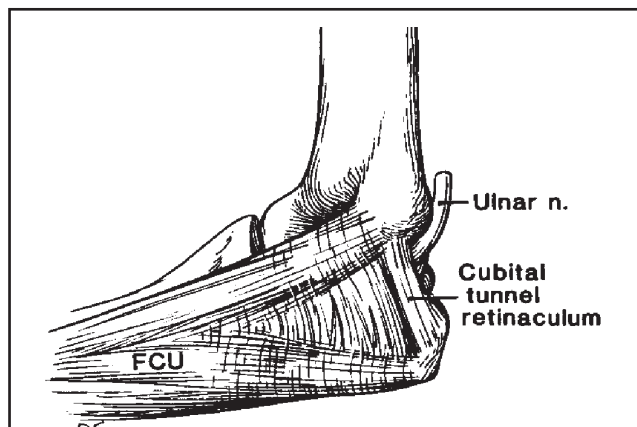


Figure 1: The proximal edge of the roof of the cubital tunnel is formed by a retinaculum that originates on the medial epicondyle and inserts on the olecranon. It is distinct from the aponeurosis of the flexor carpi ulnaris (FCU) with which its distal margin blends. From O'Driscoll SW, et al: J Bone Joint Surg 1991; 73-B:613-617, with permission.

study of ulnar neuropathy in 1,502 surgical patients found that none of the patients developed symptoms of the neuropathy during the first two postoperative days.¹⁰

Currently available data suggest that perioperative ulnar neuropathy may be caused by factors other than improper patient positioning and padding of extremities during surgery. Elbow flexion, especially to greater than 100°, can elongate the ulnar nerve and tightening the cubital tunnel retinaculum, directly compressing the ulnar nerve (Figures 1-3).¹¹⁻¹³ The

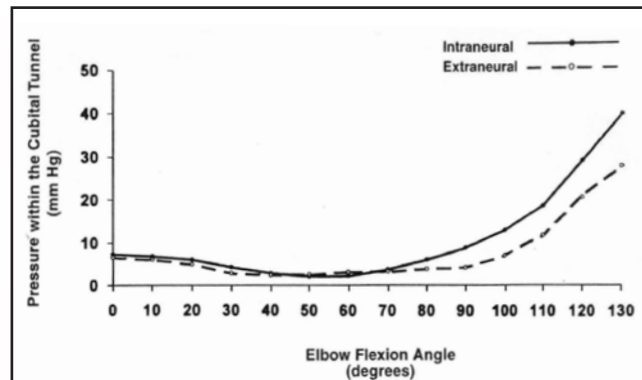


Figure 2: Intraneural and extraneural pressures for the ulnar nerve within the cubital tunnel increased dramatically with elbow flexion greater than 100°. From Gelberman RH, et al: J Bone Joint Surg 1998; 80:492-501, with permission.

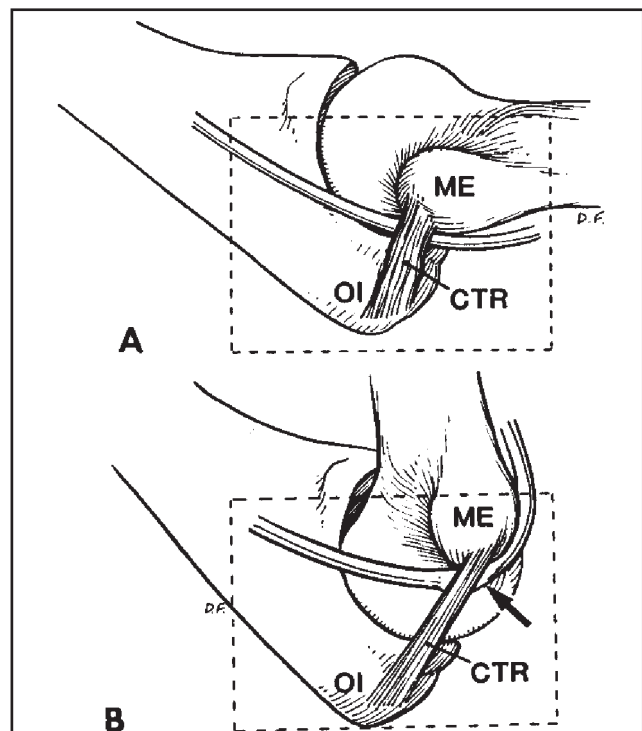


Figure 3: In this medial-to-lateral view of the right elbow, the cubital tunnel retinaculum (CTR) is lax in extension (A) as it stretches from the medial epicondyle (ME) to the olecranon (OI). The retinaculum tightens in flexion (B) and can compress the ulnar nerve (arrow). From O'Driscoll SW, et al: J Bone Joint Surg 1991; 73-B:613-617, with permission.

clinical significance of this finding, however, is unclear. Morell et al¹⁴ found that elbow flexion did not inhibit ulnar nerve perception, while direct pressure on the ulnar nerve in the post-condylar groove did.

External compression of the ulnar nerve in the absence of elbow flexion also may damage the nerve. Compression within the bony groove posterior to the medial epicondyle may be possible. In a very innovative study Prielipp et al¹⁵ have shown that forearm rotation, especially pronation, can increase pressure in the postcondylar groove (Figure 4). Contreras et al¹⁶ have noted that the nerve may be more easily compressed by external forces distal to the medial epicondyle where the nerve and its associated artery are quite superficial than in the postcondylar groove (Figure 5).

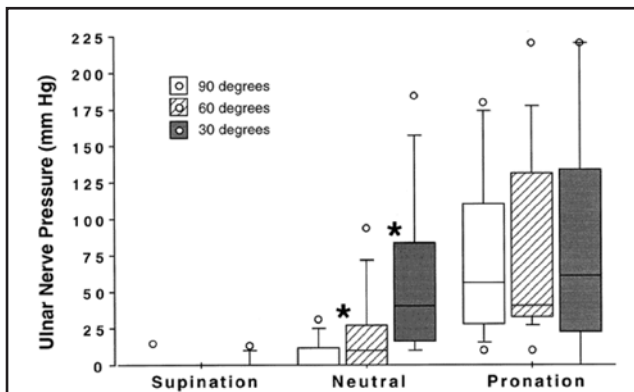


Figure 4: In supination, the pressure over the ulnar nerve is uniformly low, and most of the data are clustered around the zero line. Prielipp RC, et al: *Anesthesiology* 1999; 91:345-354.

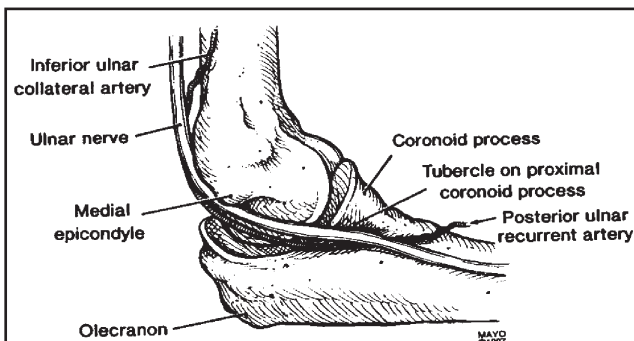


Figure 5: The ulnar nerve and its primary blood supply in the proximal forearm, the posterior ulnar recurrent artery, are very superficial and appear to be susceptible to compression from external pressure as they pass posteriomedially to the tubercle of the coronoid process. The tubercle is larger in men than women, and the adipose layer in this area is thinner in men.¹⁶

Brachial plexus neuropathy

Brachial plexus neuropathies may masquerade as ulnar neuropathies or be associated with symptoms that suggest injuries to other nerve structures. In general, brachial plexus neuropathies are associated with median sternotomy.¹⁷⁻¹⁹ This neuropathy often involves stretch or compression of the brachial

plexus during sternal separation.^{18,19} Other potential mechanisms of injury include direct trauma from fractured first ribs. In general, brachial plexus neuropathy does not appear to be related to a patient's arm position or padding during the sternotomy and related procedures.²⁰

The brachial plexus is also vulnerable to stretch in a patient who is positioned prone (Figure 6).²¹ Stretch of the brachial plexus, especially its lower trunks, is most likely to occur when the head is turned to the contralateral side, the ipsilateral shoulder is abducted, and the ipsilateral elbow is bent. Other potential problems are noted in the legend for Figure 6. Although this position is commonly used during surgical procedures and the frequency of perioperative brachial plexus neuropathy is low, it would appear prudent to place the arms at the patient's side whenever possible to decrease the risk of brachial plexus stretching. Kamel and colleagues have recently shown that the frequency of SSEP (somato-sensory evoked potential) abnormalities is 3-fold less with arms tucked at the side than elevated in a "surrender" position.²²

LOWER EXTREMITY NEUROPATHIES

Although neuropathies of the lower extremities may occur in a variety of patient postures, most of these occur in patients who are undergoing procedures while placed in a lithotomy position. These neuropathies have often been considered to be preventable and to occur because of poor intraoperative care (e.g. improper positioning or padding) or judgment (e.g. excessively prolonged use of lithotomy position).²³ This perception has significant impact on the outcomes of medicolegal cases involving these types of problems.²⁴ Interestingly, the majority of plaintiffs in medicolegal cases involving lower extremity neuropathies name anesthesiologists and surgeons in their complaints. In contrast, plaintiffs in cases involving upper extremity nerves often do not name surgeons.

A number of studies have suggested that there are many factors other than improper intraoperative care that may contribute to the risk of lower extremity nerve injury.²⁵⁻²⁷ A 1994 retrospective review of patients in lithotomy positions found that the most common lower extremity neuropathies were the common peroneal (81%), sciatic (15%), and femoral (4%).²⁸ The authors found specific patient characteristics that contributed to the risk of neuropathy. A more recent prospective study found that the longer patients were in lithotomy, the greater their risk of developing a neuropathy.²⁹ The obturator and lateral femoral cutaneous (LFC) nerve were most often involved in this study.

Obturator and Lateral Femoral Cutaneous Neuropathies

Litwiller et al³⁰ subsequently evaluated the strain of the obturator and LFC nerves associated with

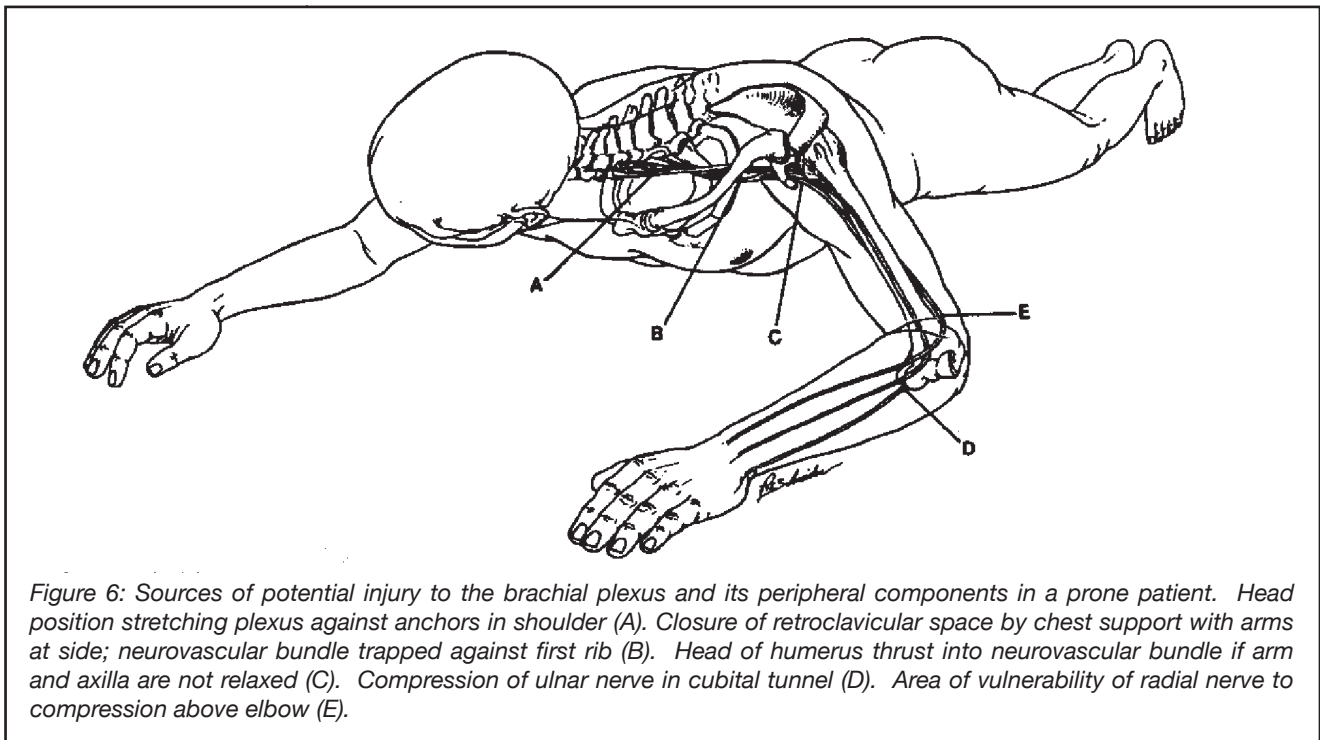


Figure 6: Sources of potential injury to the brachial plexus and its peripheral components in a prone patient. Head position stretching plexus against anchors in shoulder (A). Closure of retroclavicular space by chest support with arms at side; neurovascular bundle trapped against first rib (B). Head of humerus thrust into neurovascular bundle if arm and axilla are not relaxed (C). Compression of ulnar nerve in cubital tunnel (D). Area of vulnerability of radial nerve to compression above elbow (E).

lithotomy positions in fresh cadavers. They found that neither hip flexion nor abduction increased strain on the LFC nerve. However, abduction to $>30^\circ$ without concomitant hip flexion dramatically increased strain on the obturator nerve.

Common Peroneal Neuropathy

The common peroneal nerve is very superficial as it wraps around the head of the fibula. Because it is quite exposed at this level, it may easily be compressed and injured. Although direct compression of the peroneal nerve by leg holders has commonly been considered the primary mechanism of injury in peroneal neuropathy, a recent study suggests that the superficial peroneal nerve may be affected distal to the fibular head.²⁹ The authors speculated that compressive stockings or wraps may be aetiologic factors for this finding.

Sciatic Neuropathy

The same forces that contribute to stretch injuries of the hamstring group muscles (e.g. biceps femoris muscle) may stretch the sciatic nerve. Simultaneous hyperflexion of the hip and extension of the knee will stretch and possibly injure the sciatic nerve. This set of actions can occur during the establishment and maintenance of a lithotomy position. A patient in a lithotomy position may passively shift towards the caudal end of an operating table when placed in a head-up posture or be actively shifted caudally by a member of the operating team, in an attempt to obtain increased exposure of the perineum. This movement may increase the flexion of the hips and extension of the legs, if the legs are already fixated within leg holders. It would seem prudent to confirm that the flexor muscles of the knee (e.g. hamstring group) are not taut after placing a patient's legs into any lithotomy position.

Femoral Neuropathy

Unlike most other neuropathies in which the anaesthesia provider is often considered to have acted improperly in order for the neuropathy to occur, those involving the femoral nerve and its cutaneous branches often are considered to result from improper placement of abdominal wall retractors and direct compression of the nerve. When related to retractors, the assumption is that retractors place continuous pressure on the iliopsoas muscle and either stretch the nerve or cause it to become ischemic by occluding the external iliac artery or penetrating vessels of the nerve as it passes through the muscle.³¹

PRACTICAL CONSIDERATIONS FOR NEUROPATHIES

Efforts to prevent perioperative neuropathies are frequently debated, and there is often confusion on how to manage a neuropathy once it has occurred. In general, there are no data to support recommendations on any of these issues. Therefore, the following opinions have been formulated by personal experience, guided by advice from neurologists who primarily care for patients with peripheral neuropathies, and seasoned or supported by speculation derived from anecdotal case reports.

Padding exposed peripheral nerves

Many types of padding materials are advocated to protect exposed peripheral nerves. They often consist of cloth (e.g. blankets and towels), foam sponges (e.g. "eggcrate" foam), and gel pads. There are no data to suggest that any of these materials is more effective than any other, or that any is better than no padding at all. A good rule-of-thumb would be to position and pad exposed peripheral nerves to (1) prevent their stretch beyond normally tolerated limits while awake,

- (2) avoid their direct compression, if possible, and
- (3) distribute over as large an area as possible any compressive forces that must be placed on them.

What to do if your patient develops a neuropathy?

Although each situation is unique and requires careful assessment, the following guidelines may suggest a basic course of action that will lead to appropriate care:

- **Is the neuropathy sensory or motor?** Sensory lesions are more frequently transient than motor lesions. If the symptoms are numbness and/or tingling only, it may be appropriate to inform the patient that many of these neuropathies will resolve during the first 5 days.¹⁰ The patient should be instructed to avoid postures that might compress or stretch the involved nerve. Arrangements should be made for frequent contact with the patient. A call to alert a neurologist would be appropriate, and if the symptoms still persist on postoperative day 5, the neurologist should be consulted.
- **If the neuropathy has a motor component,** a neurologist should be consulted immediately. Electromyographic studies may be needed to assess the location of any acute lesion. This knowledge may direct an appropriate treatment plan. The studies may also demonstrate chronic abnormalities of the nerve or, if applicable, the contralateral nerve.

BLINDNESS

Over the past decade there has been speculation that the frequency of perioperative blindness has been increasing, especially in patients undergoing procedures while positioned prone for prolonged periods (e.g. major spine surgeries). Interestingly, there are few data to support this speculation. The rate of spinal fusion procedures has, however, increased in the past decade and may be a contributing factor.³² It appears that most non-surgically related postoperative vision loss occurs in patients undergoing cardiac procedures, followed in frequency by patients undergoing spine surgery.³³

Potential Pathologies

In the absence of surgical excision or trauma to visual tissues, most cases involve anterior or posterior ischemic optic neuropathy (AION and PION, respectively), central retinal artery occlusion, or undefined ischemia to the cerebral cortex. There are very few cases reported in the past 2 decades in which direct pressure to the globe is implicated in perioperative blindness. Blindness in cardiac patients is approximately balanced between AION and PION. In contrast, PION appears to be the predominant problem in prone-positioned patients.

The aetiology of PION is unknown. There is no doubt that prone-positioned, anesthetised patients develop an increase in intraocular pressure.³⁴⁻³⁶ This increase

appears related, in part, to the impact of gravity and increased central venous pressure in prone-positioned patients.^{34,37} Posture-induced changes in the anatomy and function of the iris and lens also may contribute.³⁸ This potential contribution of intraocular anatomy in prone-positioned patients has been supported by the finding that timolol solution can attenuate the increase in intraocular pressure.³⁹ Anemia and hypotension have been considered potential aetiologies, primarily based on information propagated by isolated case reports and small case series,^{40,41} but an exhaustive review on this topic, as it pertains to spine surgery patients, has found no evidence of an association between these factors and perioperative visual loss.⁴² Periorbital oedema may occur in prone-positioned patients, or vertically-inverted study subjects,^{43,44} but this oedema does not appear to be correlated with visual loss.⁴² There is speculation (without data) that engorgement of the veins in and around the optic nerve and its sheath may cause compartment compression of the optic nerve sheath, limiting arterial perfusion to its posterior extension. This posterior extension of the nerve just anterior to the optic chiasm, has few major arterial vessels and may have an increased risk of low perfusion.⁴⁵

Risk Factors

There are sufficient numbers of cases in cardiac surgical patients to retrospectively determine risk factors for this problem. Nuttall et al⁴⁶ found in cardiac surgical patients that patient factors (advanced age and arteriosclerosis), procedure issues (prolonged pump perfusion and surgical disruption of particulate matter), and practice patterns (deliberate postoperative anemia and intraoperative hypotension) are associated with an increased frequency of vision loss. There are insufficient numbers of cases in any series to evaluate risk factors in non-cardiac surgical patients. However, a recent report from the ASA's Closed Claims Postoperative Visual Loss Registry suggests that most cases of vision loss in spinal surgery occur in patients who are positioned prone, undergo procedures lasting more than 6 hours, and who experience substantial blood loss.⁴⁷

General Guidelines

The conclusions of the ASA Task Force on Perioperative Blindness are shown in Table 1.⁴²

SEVERAL POTENTIAL CATASTROPHIC POSITIONING PROBLEMS

Spinal cord ischemia or infarction from lumbar hyperextension

Many patients who undergo pelvic procedures using an abdominal approach are positioned supine with their lumbar spines hyperextended in an attempt to increase surgeon visibility into the lower pelvis. This practice is reasonable as long as the mechanism for hyperextending the lumbar spine is limited to the maneuvers allowed by operating room tables (e.g. raising the kidney rest). Tables manufactured within

Table 1

- There is a subset of patients who undergo spinal procedures, while they are positioned prone and receiving general anesthesia, that has an increased risk for development of perioperative visual loss. This subset includes patients who are anticipated preoperatively to undergo procedures that are prolonged, have substantial blood loss, or both (high-risk patients).
- Consider informing high-risk patients that there is a small, unpredictable risk of perioperative visual loss.
- The use of deliberate hypotensive techniques during spine surgery has not been shown to be associated with the development of perioperative visual loss.
- Colloids should be used along with crystalloids to maintain intravascular volume in patients who have substantial blood loss.
- At this time, there is no apparent transfusion threshold that would eliminate the risk of perioperative visual loss related to anemia.
- High-risk patients should be positioned so that their heads are level with or higher than the heart when possible. In addition, their heads should be maintained in a neutral forward position (i.e. without significant neck flexion, extension, lateral flexion, or rotation) when possible.
- Consideration should be given to the use of staged spine procedures in high-risk patients.

the U.S. do not allow hyperextension of the lumbar spine to greater than 10°. When excessive padding is introduced under the lumbar spine to gain additional hyperextension, however, the degree of hyperextension may exceed 10°. The 10° angle is important because there are no reports of anterior spinal cord ischemia when patients are positioned using only the table mechanisms to induce lumbar hyperextension. When additional padding or other maneuvers are used to increase hyperextension, however, the spinal cord may become ischemic and infarct.⁴⁸

Thoracic outlet obstruction

Elevation of the arms at the shoulders to greater than 90° abduction may be associated with thoracic outlet obstruction in some patients. Patients positioned prone and who may have their shoulders abducted to greater than 90° (i.e. a “surrender” position) should be asked preoperatively if elevation of their arms causes cold, pain, or tingling. These symptoms suggest potential for thoracic outlet obstruction and should be considered when positioning patients. Most patients are most comfortable with their arms at their sides when positioned prone, and many procedures in prone-positioned patients can be performed when the arms are tucked at the sides.

References

1. Kroll DA, Caplan RA, Posner K, Ward RJ, Cheney FW: Nerve injury associated with anesthesia. *Anesthesiology* 1990; 73: 202-7
2. Cheney FW, Domino KB, Caplan RA, Posner KL: Nerve injury associated with anesthesia: a closed claims analysis. *Anesthesiology* 1999; 90: 1062-9
3. Dawson DM, Krarup C: Perioperative nerve lesions. *Arch Neurol* 1989; 46: 1355-60
4. Büdinger K: Ueber Lähmungen nach chloroform-narkosen. *Arch f Kin Chirc* 1894; 47: 121-145
5. Garriques HJ: Anaesthesia-paralysis. *Am J Med Sci* 1897; 133: 81-89

6. Wadsworth TG, Williams JR: Cubital tunnel external compression syndrome. *Br Med J* 1973; 1: 662-6
7. Warner MA, Warner DO, Harper CM, Schroeder DR, Maxson PM: Ulnar neuropathy in medical patients. *Anesthesiology* 2000; 92: 613-5
8. Warner MA, Warner ME, Martin JT: Ulnar neuropathy. Incidence, outcome, and risk factors in sedated or anesthetized patients. *Anesthesiology* 1994; 81: 1332-40
9. Alvine FG, Schurrer ME: Postoperative ulnar-nerve palsy. Are there predisposing factors? *J Bone Joint Surg Am* 1987; 69: 255-9
10. Warner MA, Warner DO, Matsumoto JY, Harper CM, Schroeder DR, Maxson PM: Ulnar neuropathy in surgical patients. *Anesthesiology* 1999; 90: 54-9
11. O’Driscoll SW, Horii E, Carmichael SW, Morrey BF: The cubital tunnel and ulnar neuropathy. *J Bone Joint Surg Br* 1991; 73: 613-7
12. Gelberman RH, Yamaguchi K, Hollstien SB, Winn SS, Heidenreich FP, Jr., Bindra RR, Hsieh P, Silva MJ: Changes in interstitial pressure and cross-sectional area of the cubital tunnel and of the ulnar nerve with flexion of the elbow. An experimental study in human cadavera. *J Bone Joint Surg Am* 1998; 80: 492-501
13. Grewal R, Varitimidis SE, Vardakas DG, Fu FH, Sotereanos DG: Ulnar nerve elongation and excursion in the cubital tunnel after decompression and anterior transposition. *J Hand Surg [Br]* 2000; 25: 457-60
14. Morell RC, Prielipp RC, Harwood TN, James RL, Butterworth JF: Men are more susceptible than women to direct pressure on unmyelinated ulnar nerve fibers. *Anesth Analg* 2003; 97: 1183-8, table of contents
15. Prielipp RC, Morell RC, Walker FO, Santos CC, Bennett J, Butterworth J: Ulnar nerve pressure: influence of arm position and relationship to somatosensory evoked potentials. *Anesthesiology* 1999; 91: 345-54
16. Contreras MG, Warner MA, Charboneau WJ, Cahill DR: Anatomy of the ulnar nerve at the elbow: potential relationship of acute ulnar neuropathy to gender differences. *Clin Anat* 1998; 11: 372-8

17. Hickey C, Gugino LD, Aglio LS, Mark JB, Son SL, Maddi R: Intraoperative somatosensory evoked potential monitoring predicts peripheral nerve injury during cardiac surgery. *Anesthesiology* 1993; 78: 29-35
18. Vahl CF, Carl I, Muller-Vahl H, Struck E: Brachial plexus injury after cardiac surgery. The role of internal mammary artery preparation: a prospective study on 1000 consecutive patients. *J Thorac Cardiovasc Surg* 1991; 102: 724-9
19. Roy RC, Stafford MA, Charlton JE: Nerve injury and musculoskeletal complaints after cardiac surgery: influence of internal mammary artery dissection and left arm position. *Anesth Analg* 1988; 67: 277-9
20. Jellish WS, Blakeman B, Warf P, Slogoff S: Hands-up positioning during asymmetric sternal retraction for internal mammary artery harvest: a possible method to reduce brachial plexus injury. *Anesth Analg* 1997; 84: 260-5
21. Martin JT: The ventral decubitus (prone) positions, Positioning in Anesthesia and Surgery, 3rd Edition. Edited by Martin JT, Warner MA. Philadelphia, W.B. Saunders Company, 1997, pp 155-195
22. Kamel IR, Drum ET, Koch SA, Whitten JA, Gaughan JP, Barnette RE, Wendling WW. *Anesth Analg* 2006;102:1538-42
23. Dornette WH: Compression neuropathies: medical aspects and legal implications. *Int Anesthesiol Clin* 1986; 24: 201-29
24. Dornette WHL: Identifying, moving, and positioning the patient, *Legal Issues in Anesthesia Practice*. Edited by Dornette WHL. Philadelphia, FA Davis, 1991, pp 120-123
25. Rose HA, Hood RW, Otis JC, Ranawat CS, Insall JN: Peroneal-nerve palsy following total knee arthroplasty. A review of The Hospital for Special Surgery experience. *J Bone Joint Surg Am* 1982; 64: 347-51
26. James SE, Wade PJ: Lateral popliteal nerve palsy as a complication of the use of a continuous passive motion knee machine--a case report. *Injury* 1987; 18: 72-3
27. Weber ER, Daube JR, Coventry MB: Peripheral neuropathies associated with total hip arthroplasty. *J Bone Joint Surg Am* 1976; 58: 66-9
28. Warner MA, Martin JT, Schroeder DR, Offord KP, Chute CG: Lower-extremity motor neuropathy associated with surgery performed on patients in a lithotomy position. *Anesthesiology* 1994; 81: 6-12
29. Warner MA, Warner DO, Harper CM, Schroeder DR, Maxson PM: Lower extremity neuropathies associated with lithotomy positions. *Anesthesiology* 2000; 93: 938-42
30. Litwiller JP, Wells RE, Jr., Halliwill JR, Carmichael SW, Warner MA: Effect of lithotomy positions on strain of the obturator and lateral femoral cutaneous nerves. *Clin Anat* 2004; 17: 45-9
31. Rosenblum J, Schwarz GA, Bendler E: Femoral neuropathy--a neurological complication of hysterectomy. *Jama* 1966; 195: 409-14
32. Deyo RA, Gray DT, Kreuter W, Mirza S, Martin BI. United States trends in lumbar fusion surgery for degenerative conditions. *Spine* 2005;30: 1441-5; discussion 1446-7
33. Warner MA. Postoperative visual loss: Experts, data, and practice. *Anesthesiology* 2006; 105:641-2
34. Lee LA, Vavilala MS, Sires BS, Chapman J, Lam AM: Intraocular pressure is partially dependent on central venous pressure during prone spine surgery. *Anesthesiology* 2003; 99: A289
35. Murphy DF: Anesthesia and intraocular pressure. *Anesth Analg* 1985; 64: 520-30
36. Cheng MA, Todorov A, Tempelhoff R, McHugh T, Crowder CM, Lauryssen C: The effect of prone positioning on intraocular pressure in anesthetized patients. *Anesthesiology* 2001; 95: 1351-5
37. Ozcan MS, Praetel C, Bhatti MT, Mahla ME, Seubert CN: The effect of body inclination during prone positioning on intraocular pressure in awake volunteers: Comparison of two operating tables. *Anesthesiology* 2003; 99: A363
38. Lam AK, Douthwaite WA: Does the change of anterior chamber depth or/and episcleral venous pressure cause intraocular pressure change in postural variation? *Optom Vis Sci* 1997; 74: 664-7
39. Caiati J, Eliazo R, Lien C, Mack PF: Timolol prevents the dramatic increase in intra-ocular pressure (IOP) associated with prone positioning for spine surgery. *Anesthesiology* 2003; 99: A309
40. Roth S, Barach P: Postoperative visual loss: still no answers--yet. *Anesthesiology* 2001; 95: 575-7
41. Brown RH, Schauble JF, Miller NR: Anemia and hypotension as contributors to perioperative loss of vision. *Anesthesiology* 1994; 80: 222-6
42. American Society of Anesthesiologists Task Force on Perioperative Blindness. Practice advisory for perioperative visual loss associated with spine surgery. *Anesthesiology* 2006; 104:1319-28
43. Draeger J, Hanke K: Postural variations of intraocular pressure--preflight experiments for the D1-mission. *Ophthalmic Res* 1986; 18: 55-60
44. Friberg TR, Weinreb RN: Ocular manifestations of gravity inversion. *Jama* 1985; 253: 1755-7
45. Hayreh SS. *Prog Retin Eye Res* 2001;20:563-93
46. Nuttall GA, Garrity JA, Dearani JA, Abel MD, Schroeder DR, Mullany CJ: Risk factors for ischemic optic neuropathy after cardiopulmonary bypass: a matched case/control study. *Anesth Analg* 2001; 93: 1410-6, table of contents
47. Lee LA, Roth S, Posner KL, Cheney FW, Caplan RA, Newman NJ, Domino KB. The American Society of Anesthesiologists postoperative visual loss registry: analysis of 93 spine surgery cases with postoperative visual loss. *Anesthesiology* 2006; 105: 652-9
48. Amoiridis G, Wohrle JC, Langkafel M, Maiwurm D, Przuntek H: Spinal cord infarction after surgery in a patient in the hyperlordotic position. *Anesthesiology* 1996; 84: 228-30