

Anaesthesia for foot and ankle surgery - general and regional techniques

Joe Loader*, Bruce McCormick

*Corresponding author. Email: jloader@doctors.org.uk

Summary

Regional and general techniques to provide anaesthesia and postoperative analgesia for foot and ankle surgery are discussed. Spinal anaesthesia is appropriate for shorter procedures, whereas general anaesthesia in combination with a regional technique is generally used for procedures over two hours. Ankle block and sciatic nerve block at the knee provide effective perioperative analgesia and both are described in detail.

INTRODUCTION

Anaesthesia for foot and ankle surgery can be provided by general or loco-regional anaesthesia and, given the peripheral site of surgery, a combination of both is generally well-tolerated. Regional anaesthesia confers excellent analgesia postoperatively, reducing the requirements for systemic analgesics. Anaesthetic techniques are usefully divided into those appropriate for surgery to the foot and those for surgery to the ankle.

If you are unsure about your choice of an appropriate regional technique, talk to the surgeon to clarify the site of surgery and incision, and the anticipated postoperative pain.

ANATOMY

The sensory supply to the foot and ankle is shared between branches of the femoral and sciatic nerves. The motor supply is almost exclusively from the posterior tibial nerve (a branch of the sciatic nerve).

Femoral nerve (L2-4)

The terminal branches form the saphenous nerve (L3-4), which supplies the skin over the

medial malleolus, the medial aspect of the foot, with variable innervation to the head of the first metatarsal.

Sciatic nerve (L4-S3)

The sciatic nerve divides into the tibial and common peroneal nerves at a variable level between the buttock and popliteal fossa. Commonly this is about 6-10 cm proximal to the posterior knee skin crease, but may occur more proximally in up to 30% of patients.

The tibial nerve supplies motor nerves to the flexor muscles of the calf and foot, and divides into the posterior tibial and sural nerves. The posterior tibial nerve passes posteriorly to the medial malleolus, running just posterior to the tibial artery. It then divides into the medial and lateral plantar nerves in the foot, which supply motor innervation to the foot and sensory nerves to the internal structures of the foot and skin over the sole of the foot. The sural nerve supplies sensation to the lateral aspect of the heel and foot, with the calcaneal branch of the tibial nerve supplying the remaining parts of the heel.

The common peroneal nerve winds around the head of the fibula and then divides into

Joe Loader

Specialist Registrar
in Anaesthesia
Royal Devon and Exeter
NHS Foundation Trust
Barrack Road
Exeter
EX2 5DW
UK

Bruce McCormick

Consultant Anaesthetist
Royal Devon and Exeter
NHS Foundation Trust
Barrack Road
Exeter
EX2 5DW
UK

Table 1. Foot and ankle surgery

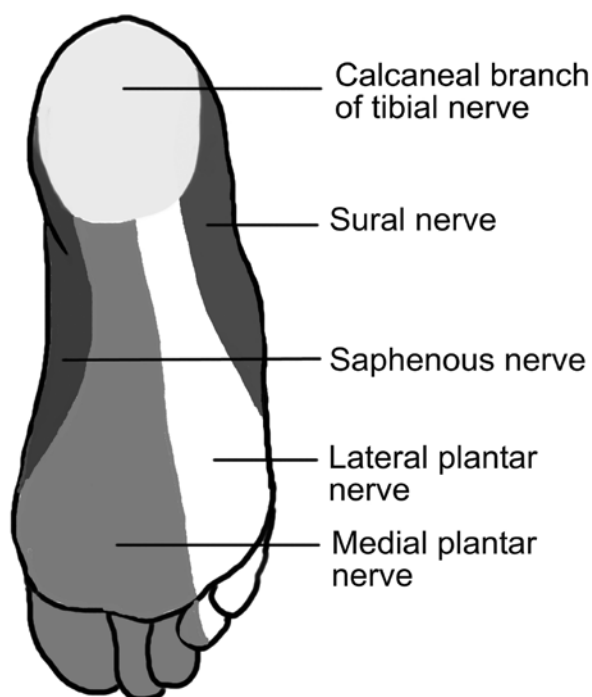
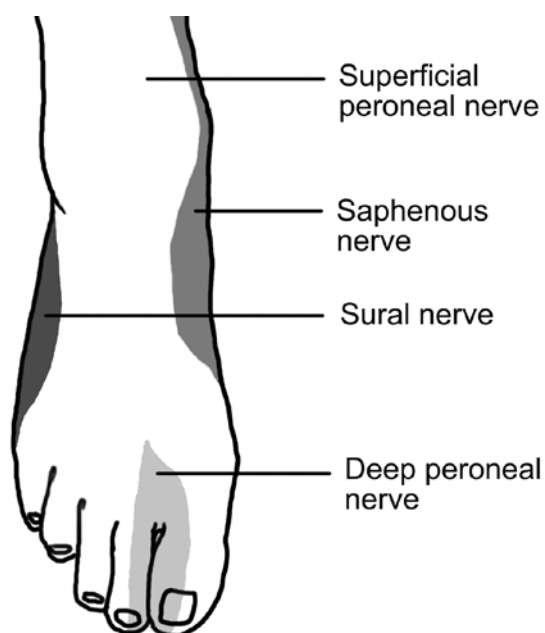
Site of surgery	Examples	Anaesthetic technique
Foot (i.e. midfoot, forefoot and toes)	<ul style="list-style-type: none">• Scarf osteotomy (bunionectomy)• Weil osteotomy• Calcaneal fracture repair	General with ankle block or Spinal if surgery less than 1½ - 2 hours
Ankle	<ul style="list-style-type: none">• Ankle arthroscopy• Arthrodesis (e.g. tibio-talar fusion)• Ankle replacement	General with more proximal block (e.g. popliteal block) or Spinal if surgery less than 1½ - 2 hours

superficial and deep branches, supplying the dorsum of the foot and ankle, and the first web space respectively.

ANAESTHESIA FOR FOOT SURGERY

General points

- General anaesthesia (GA) with an ankle block, or spinal anaesthesia is usually appropriate. Where patient choice or medical co-morbidities dictate, spinal anaesthesia may be used for procedures lasting less than 1½ to



Figures 1 and 2. Sensory innervation of the foot and ankle

2 hours. Ankle block is usually combined with general anaesthesia, but may be used as the sole anaesthetic in patients who are unfit for GA. Be aware that the onset time is usually in excess of 30–40 minutes and that performing the block is painful and some form of sedation is recommended.

- Longer-acting local anaesthetic agents are preferred and generally provide analgesia for 12 hours or greater.
- The maximal safe dose for bupivacaine is 2mg.kg⁻¹. Where only lignocaine is available 3mg.kg⁻¹ can be used; this can be increased to 7mg.kg⁻¹ if epinephrine is added, but this is not advisable for ankle block due to the risk of causing ischaemia of the foot. Analgesia may be prolonged by the addition of clonidine to the local anaesthetic.
- Where available local anaesthetic catheters may be placed for longer term use in the postoperative period.
- Check the block prior to surgery, testing sensation to pinprick.
- If anaesthesia is inadequate, identify which nerve supplies the relevant area and repeat the infiltration of that nerve.
- Within the limits of maximal local anaesthetic doses, advise the surgeon to infiltrate locally during surgery to augment the block.

ANKLE BLOCK

Preparation

1. Check resuscitation equipment and drugs.
2. Perform block in an anaesthetic or operating room.
3. Explain procedure to patient and obtain consent.
4. Establish IV access.
5. Full monitoring is advised where available (ECG, pulse oximetry, NIBP).

Technique - general

- Performing the block is painful so remember to inject the local anaesthetic (LA) slowly. Heating the local anaesthetic to body temperature may also help to reduce pain. Sedation is usually required.
- All five nerves can be blocked with the patient supine and the foot on a padded support. Some prefer to block the **posterior tibial** and **sural nerves** with the patient prone. To block the posterior tibial nerve in a supine position, externally rotate the leg, with the

knee slightly flexed – this allows the foot to be externally rotated.

- When a nerve stimulator is not available, a 23G needle, 3-4cm in length is appropriate for all injections. It is important always to aspirate prior to injection of local anaesthetic, to exclude intravascular injection.
- The authors feel that more use of a higher concentration of local anaesthetic (e.g. 0.5% bupivacaine) improves the success of the block.
- Most foot and ankle procedures require block of the **posterior tibial** nerve, since it also provides sensory innervation to most of the internal tissues of the foot. However, it is not always essential to block all four of the remaining nerves and your choice of injections should be tailored to suit the surgical procedure. If in doubt, ask the surgeon where his incisions will be and aim to cover these areas.
- Optimise analgesia with paracetamol and, where appropriate, a non steroidal antiinflammatory agent.
- Most surgeons use a thigh or calf tourniquet for these procedures and so additional intraoperative analgesia is often required to cover this. Tourniquet pressure is usually 100mmHg above the systolic blood pressure (generally 250mmHg is chosen). The risk of ischaemic damage is reduced if the tourniquet time is limited to 2 hours. The physiological response to tourniquet pain may make it difficult to assess whether the block is working and it is unwise to wake a patient relying totally on a block to provide effective analgesia.
- Most patients are positioned supine, with a wedge under the buttock on the operative side.

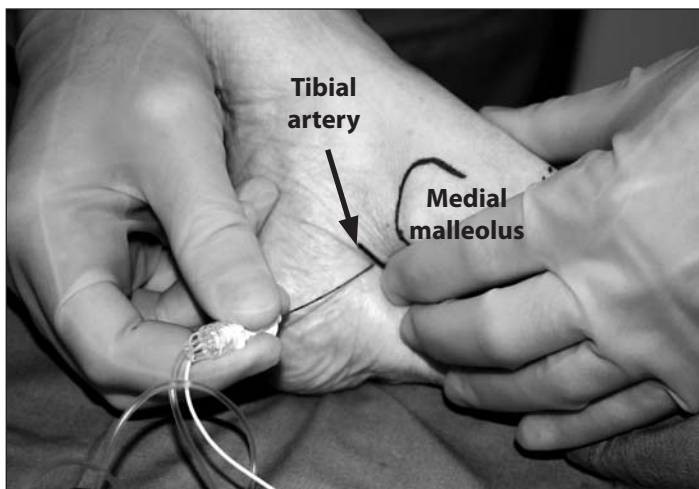


Figure 3. The posterior tibial nerve is located immediately posterior to the tibial artery behind the medial malleolus

Technique – specific nerve blocks

Always aspirate to exclude for vascular puncture before injecting local anaesthetic.

Posterior tibial nerve (this nerve can be located with a nerve stimulator – see below)

- Palpate the tibial artery just posterior and inferior to the medial malleolus. Insert the needle to pass 2-3 mm posterior to the artery (Figure 3).
- If paraesthesia is felt, inject 3-5ml LA. If not, advance to contact the tibia, withdraw 0.5cm and then inject 7-8ml LA.

Use of a peripheral nerve stimulator to locate the posterior tibial nerve.

- Of the five nerves supplying the operative field, only the **posterior tibial nerve** has a major motor supply. Where available, use of a peripheral nerve stimulator to locate this nerve behind the medial malleolus improves the success of the block (see Figure 3).
- Using a 50mm stimulator needle, look for flexion of the great toe or, less commonly, flexion of the other toes (Figure 4).
- Be aware that the threshold current for stimulation is usually higher than that achieved for other nerves and a higher value should be accepted. In practice any sort of stimulation indicates that the needle tip is close to the nerve, but it is worthwhile checking that the threshold is above 0.3mA (implying that the needle tip is not within the nerve). Be aware that conditions causing peripheral neuropathy (e.g. diabetes) may cause an abnormal or absent response to nerve stimulation.

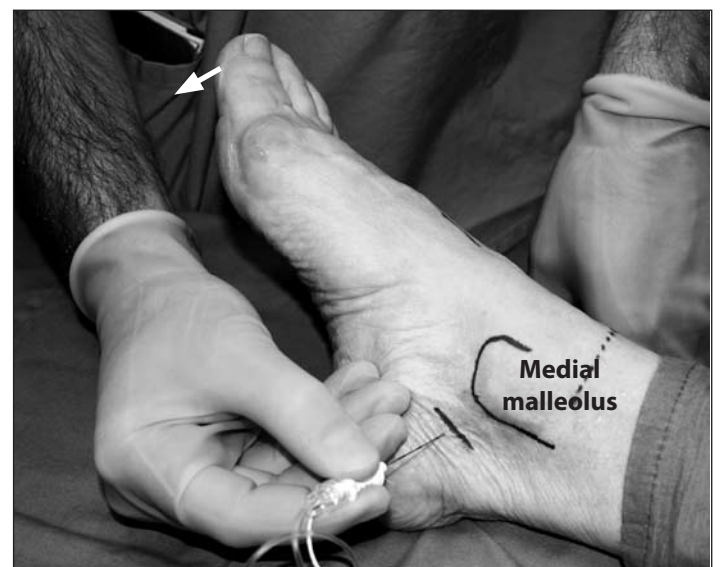


Figure 4. Successful location of the posterior tibial nerve is indicated by flexion of the hallux (arrow)

Figure 5. (A) Needle insertion point for block of superficial peroneal nerve laterally (B) and saphenous nerve medially (C)

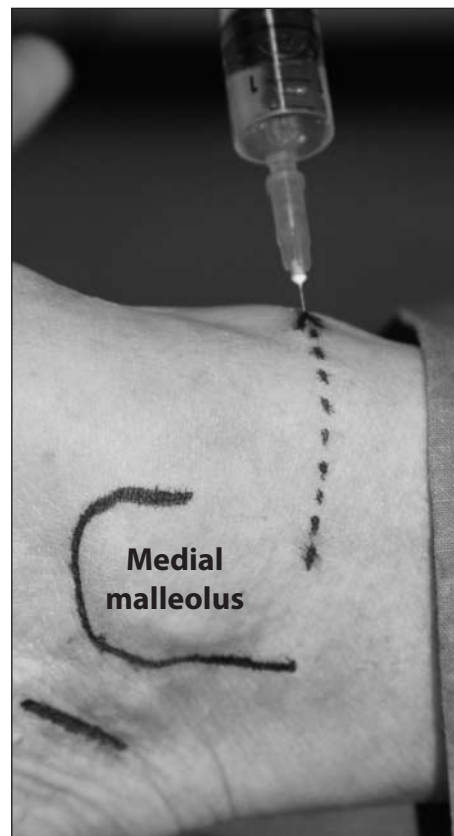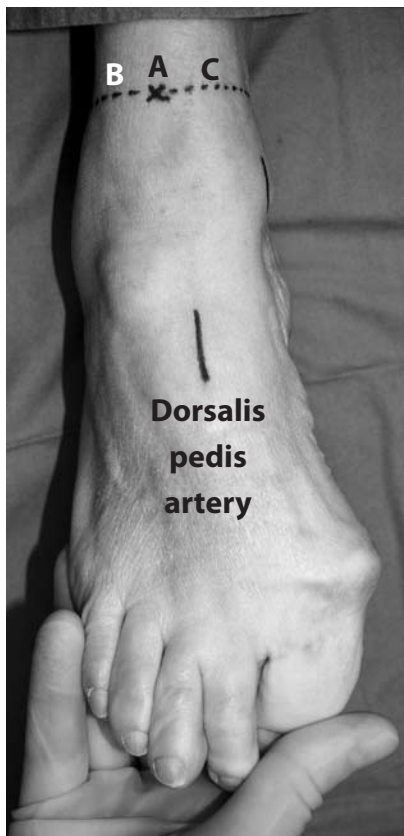


Figure 6. Block of the saphenous nerve by infiltration in a band between the needle entry point and the superior border of the medial malleolus (shown by dotted line)

- Use of a peripheral nerve stimulator reduces the volume of local anaesthetic agent required (usually 5ml for the posterior tibial nerve) and, in the authors' opinion, improves the success rate of the block (although some authors estimate the success rate at 90% without use of nerve stimulation). Block failure is overcome by supplementation with local infiltration provided by the surgeon.

Sural nerve

- Introduce the needle along the lateral border of the Achilles tendon at the level of the cephalic border of the lateral malleolus.
- Advance anteriorly towards the fibula.
- If paraesthesia is felt inject 3-5ml LA. If not, inject 5-7ml LA as the needle is withdrawn. This gives subcutaneous infiltration from the Achilles tendon to the fibula.

Superficial peroneal nerve

- Infiltration around the superficial peroneal and saphenous nerves can be performed from a single site. The needle is inserted subcutaneously at the most anterior point of the lower leg at the level of the cephalic borders of the malleoli (Figure 5).
- Turn the needle towards the lateral malleolus and inject 3ml LA in a subcutaneous band between the lateral malleolus and the anterior border of the tibia

(Figure 5). This should reach all the branches of this nerve.

Saphenous nerve

- Withdraw the needle to just stay in the skin and turn the needle to point towards the medial malleolus (Figures 5 and 6).
- Infiltrate 3ml LA subcutaneously as the needle is advanced towards the medial malleolus (Figure 6). The great saphenous vein lies in this area, just antero-medial to the medial malleolus - in order to infiltrate around the vein without causing damage, it may be necessary to make a further skin puncture lateral to the vein.

Deep peroneal nerve

- Palpate the dorsalis pedis (anterior tibial) artery. Insert your needle superficial to the artery and pass it posteriorly to the left and then right of the artery, injecting 2ml LA deep to the fascia on each side (Figure 7).
- If the artery cannot be felt, insert the needle between the tendons of extensor hallucis longis (medially) and extensor digitorum (laterally), about one third of the way down the foot from the ankle to the toes. The extensor hallucis longis tendon is prominent on the dorsum of the foot during extension of the big toe.

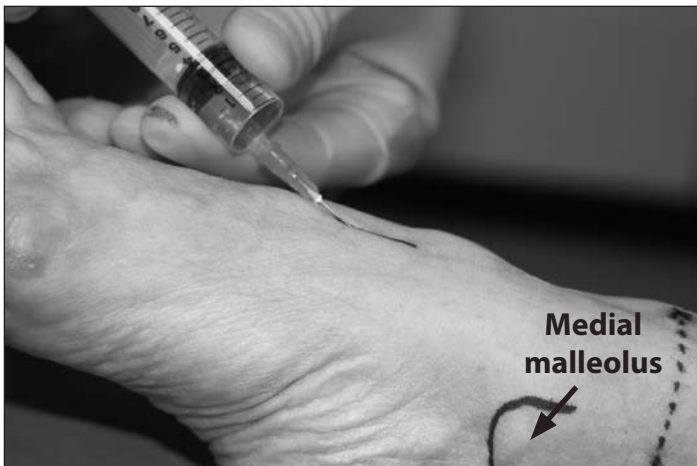

Figure 7. Block of the deep peroneal nerve using injections on either side of the tarsal tunnel

Cautions

1. It is best to avoid adrenaline in the LA. There are theoretical risks to the foot from the vasoconstrictor effect.
2. Although systemic absorption from the subcutaneous tissues of the ankle is low, and toxicity is therefore unlikely, total recommended maximum total dose of local anaesthetic should not be exceeded.

Notes for specific surgical procedures

Scarf osteotomy

- Realignment osteotomy of the first metatarsal ('bunionectomy').
- Postoperative pain is considerable.
- The surgeon makes an incision along the medial aspect of the first metatarsophalangeal joint (posterior tibial nerve, saphenous nerve and superficial peroneal nerve). Some surgeons make a second incision in the first web space (deep peroneal nerve) to release the sesamoid bones from the lateral ligaments. The sural nerve does not need to be blocked.

Weil osteotomy

- Correction of claw toe with osteotomy of the metatarsal – often multiple.
- Block the same four nerves as above and, if the fourth and fifth metatarsal bones are involved, then a sural nerve block should also be performed.
- Injection of local anaesthetic into the webspaces disrupts the surgical field and should be avoided.

Metatarsophalangeal fusion

- Usually the first metatarsal, for severe hallux valgus or pain due to osteoarthritis.

- Depends on the joints involved. Generally will require posterior tibial, saphenous, superficial and deep peroneal blocks. Sural block should be added if the 5th digit is involved.

Zadeck's procedure

- Partial nail-bed excision.
- A simple ring block of the digit can be used. Vasoconstrictors should be avoided.

Excision of Morton's neuroma

- A neuroma in the web space of the toe – often multiple.
- Although an ankle block will cover the incision(s), infiltration of local anaesthetic by the surgeon will be sufficient. Web space blocks by the anaesthetist are inappropriate since they disrupt the surgical field.

Note that for revision surgery, some surgeons prefer to make an incision in the sole of the foot – this painful approach would benefit from an ankle block.

ANAESTHESIA FOR ANKLE SURGERY

An ankle block is unlikely to provide complete analgesia for more proximal surgery. In addition, injection sites for an ankle block are likely to be at the site of surgical incision. If unsure whether to use an ankle or more proximal block, discuss the choice with the surgeon. Techniques to anaesthetise the femoral and sciatic nerves more proximally are appropriate (see Nerve blocks for anaesthesia and analgesia of the lower limb in *Update 11*, 2000, available at www.worldanaesthesia.org), however much of the motor weakness caused by a proximal sciatic nerve block can be avoided by blocking the tibial and common peroneal nerves in the popliteal fossa. This is a useful alternative for ankle (and some more proximal midfoot) surgery. These nerves can be blocked using a lateral or posterior approach. If surgery includes the medial side of the ankle, the saphenous nerve can be blocked just below the knee (see below).

SCIATIC NERVE BLOCK AT THE POPLITEAL FOSSA

Popliteal Nerve Block - Lateral approach

Indications

- Ankle and foot surgery.
- Provides anaesthesia for a calf tourniquet.

Anatomy

- The sciatic nerve lies lateral to the popliteal artery and vein (see Figure 8) and divides into the tibial and common peroneal nerves between 6 and 10cm above the popliteal crease. In 70% of individuals, this division occurs within 10cm of the popliteal crease.

Preparation

As for ankle block.

Technique

- This technique requires use of a peripheral nerve stimulator and an appropriate (usually 100mm) short bevelled needle.
- The patient is positioned supine with the leg straight and the whole leg and foot exposed. The patient is usually mildly sedated.
- The groove between vastus lateralis and biceps femoris is palpated and a position in this groove, 8 cm proximal to the popliteal crease is identified (see Figure 9). The landmarks can be accentuated by asking the patient to perform a straight leg raise. After injecting a small amount of local anaesthetic subcutaneously, insert a 100mm stimulating needle in a horizontal plane, between your two fingers pressed into the groove. Aim to hit the femur within 2-3cm of the skin

Tibial nerve	Common peroneal nerve
Plantar flexion of ankle or toes	Dorsiflexion of ankle or toes
Inversion of foot	Eversion of foot

(‘A’ in Figure 8 and Figure 10). When you have identified the femur, withdraw the needle to the skin and redirect 30 to 45° posteriorly (towards the bed) – ‘B’ in Figure 8 and Figure 11. Advance slowly towards the sciatic nerve stimulating with a current of 1.5mA. Look for movement of the foot or toes:

- The depth of the nerve is usually 5-7cm. Stimulation of the common peroneal nerve is usually encountered first, since it lies more laterally. Stimulation of either nerve is acceptable, since injection of a large volume of local anaesthetic should be sufficient to block both nerves, which lie in close proximity at this level. Aim to achieve a threshold for stimulation of 0.3 to 0.5mA. Inject 30-35ml local anaesthetic (e.g. 0.375% bupivacaine).
- Do not accept isolated twitches of the calf muscle.
- If no stimulation is achieved, first check all of your electrical connections. Then withdraw the needle and reinsert aiming a further 5-10° posteriorly. If this is still unsuccessful, repeat the process, realigning a further 5-10° posteriorly. Do not re-align anteriorly, since there is a high risk of hitting the popliteal artery or vein (see Figure 8).

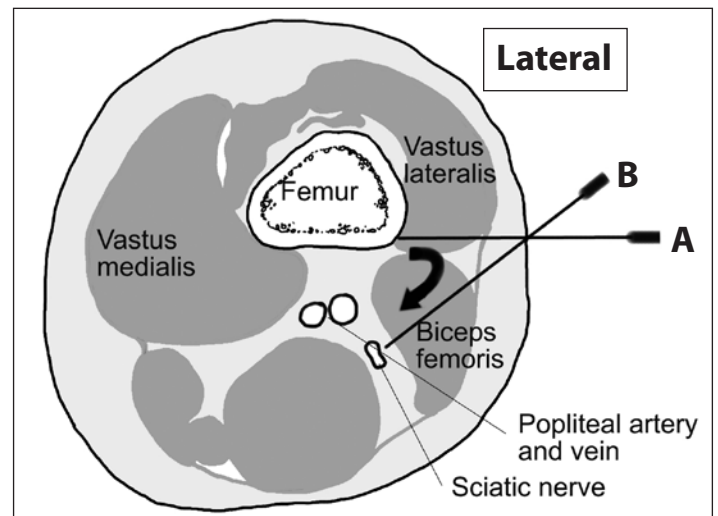


Figure 8. Cross-section through the left thigh 8cm above the popliteal crease, showing relative positions of the sciatic nerve and the popliteal artery and vein

- Remember that the skin over the medial malleolus is not covered by this block and is innervated by the saphenous nerve which can be blocked separately by a fan of local anaesthetic anterior and proximal to the medial malleolus (as described above) or at the knee (see below).

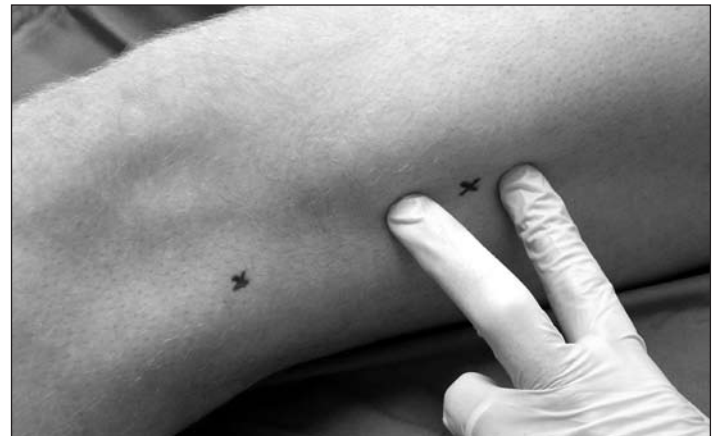

Figure 9. Palpation of the groove between vastus lateralis and biceps femoris

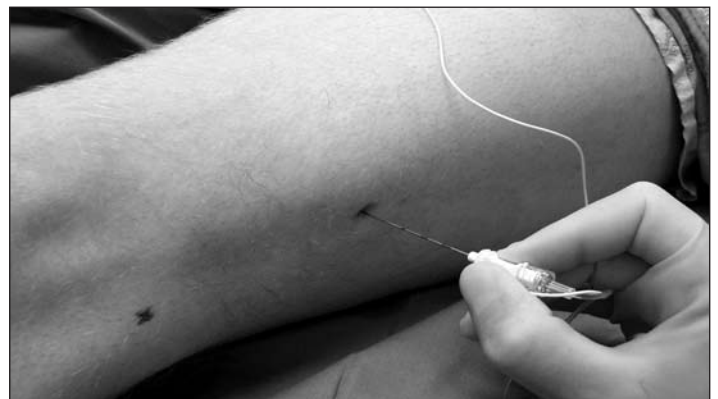

Figure 10. Needle insertion in a horizontal plane to hit the femur

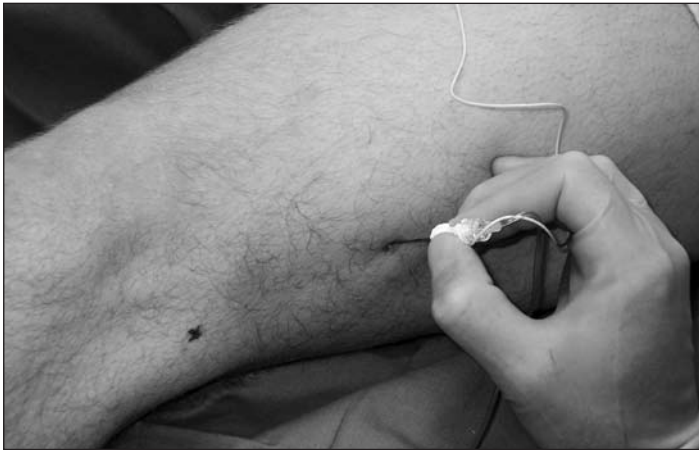


Figure 11. The needle is withdrawn to the skin and then advanced at an angle of 30-45° posteriorly (towards the bed) until calf or foot movement is seen

Potential complications

These should be discussed with the patient prior to attempting the block and include: vascular puncture, haematoma, nerve injury and failure of block.

Popliteal Nerve Block – Posterior approach

Anatomy

The popliteal fossa is bordered by the biceps femoris laterally, and by semimembranosus and semitendinosus medially, forming a triangle. The base of the triangle is formed by the popliteal crease. The sciatic nerve lies lateral to the popliteal artery and vein, dividing into the tibial and common peroneal nerves.

Technique

- The block can be performed with the patient in the prone position or supine, with the hip and knee flexed.
- With patient supine, the hip and knee are flexed to 90°, asking an assistant to support the lower leg.
- The borders and apex of the fossa are identified. A point is identified, 6-8 cm proximal to the popliteal

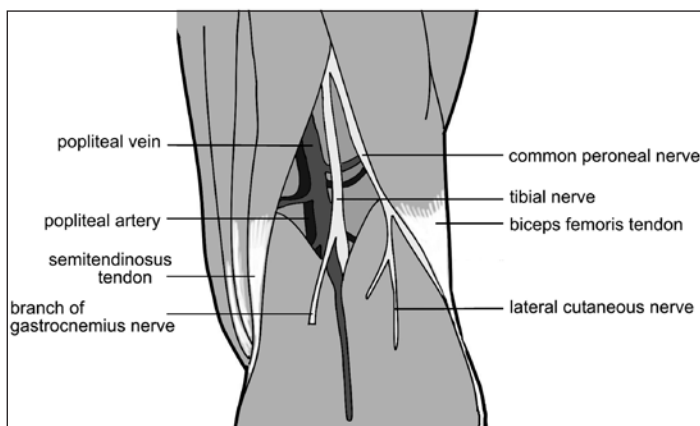


Figure 12. The anatomy of the popliteal fossa (posterior aspect).

crease, and 1 cm lateral to the midline. (The apex of the triangle is in the midline).

- Using a 50mm stimulator needle, the same end-point is sought as with the lateral approach.
- The same volume of local anaesthetic agent is used.

Complications

As for lateral approach.

SAPHENOUS NERVE BLOCK AT THE KNEE

The saphenous nerve should be blocked for all surgery involving the medial ankle. A 25G needle is inserted 2cm medial to the tibial tuberosity. A fan of local anaesthetic agent (8-10ml) is infiltrated from this site to the posterior part of the medial tibial condyle.

Notes for specific surgical procedures

Ankle/lower tibial fractures

- Neurovascular compromise for fractures involving the ankle may necessitate emergency surgery. Ensure that if the patient is insufficiently starved, you take appropriate measures during induction and emergence from general anaesthesia.
- Ask the surgeon if compartment syndrome is a risk, since more proximal blocks of the sciatic nerve may mask symptoms and should therefore be avoided.

Ankle arthroscopy – diagnostic

- Intra-articular LA injection by surgeon is sufficient.

Ankle arthroscopy – interventional (may be done as an open procedure)

- Postoperative pain is significant and popliteal block is recommended.

SUMMARY

Surgery to the foot and ankle can produce extreme intraoperative stimulation and severe postoperative pain. Use of general anaesthesia, combined with an appropriate regional technique, guided by knowledge of the surgical technique and the nerve supply of the operative area, will facilitate a smooth perioperative course and good postoperative analgesia. Spinal anaesthesia is appropriate for shorter cases.

ACKNOWLEDGEMENTS

The work of Dave Wilkinson in preparation of figures 1, 2, 8 and 9 is greatly appreciated. Thank you to Ian Sharpe, Consultant Foot and Ankle Surgeon, Royal Devon and Exeter Foundation Trust, for his advice on preparation of this manuscript.

FURTHER READING

Morphett S. Nerve blocks for anaesthesia and analgesia of the lower limb. *Update in Anaesthesia* 2000; **11**: 56-66. Available at www.worldanaesthesia.org