

## The Transversus Abdominis Plane (TAP) block: Abdominal plane regional anaesthesia

Katrina Webster

Correspondence Email: [katrina.webster@dhhs.tas.gov.au](mailto:katrina.webster@dhhs.tas.gov.au)

### Summary

TAP block involves deposition of local anaesthetic agent into the fascial plane superficial to the transversus abdominis muscle. This technique can be used for any surgery involving the lower abdominal wall, including bowel surgery, caesarean section, appendicectomy, hernia repair, umbilical surgery and gynaecological surgery. The relevant anatomy is described, followed by detailed descriptions of the landmark and ultrasound-guided techniques.

Regional anaesthesia is a rapidly evolving subspecialty area. Over recent years there has been growing interest in abdominal plane blocks, with promising data emerging on efficacy. The TAP block allows sensory blockade of the lower abdominal wall via local anaesthetic deposition above the transversus abdominis muscle.

### HISTORY OF THE TAP BLOCK

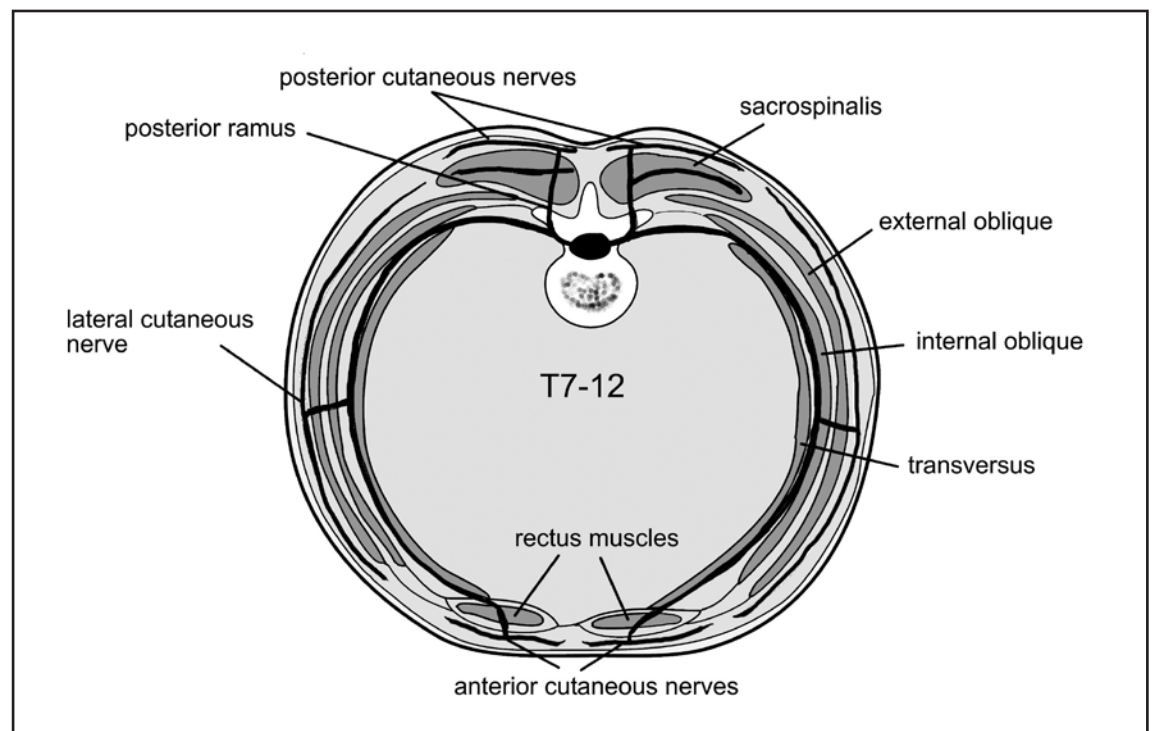
Abdominal field blocks and costo-iliac block have been used in anaesthesia for surgery involving the anterior abdominal wall for several decades. A technique involving multiple injections of local anaesthetic in the abdominal wall was used in the 1980s.<sup>1</sup> This technique was improved with a blind landmark technique, via the 'lumbar triangle of Petit'.<sup>2</sup> The clinical efficacy of the landmark technique and, more recently, ultrasound guided

techniques have been investigated in several centres around the world.<sup>3,4</sup>

### ANATOMY

Innervation of the anterolateral abdominal wall arises from the anterior rami of spinal nerves T7 to L1. Branches from the anterior rami include the intercostal nerves (T7-T11), the subcostal nerve (T12), and the iliohypogastric and ilioinguinal nerves (L1). These give rise to lateral cutaneous and anterior cutaneous branches as they become more superficial.

The intercostal nerves T7 to T11 exit the intercostal spaces and run in the neurovascular plane between the internal oblique and the transversus abdominis muscles. The subcostal nerve (T12) and the ilioinguinal and iliohypogastric nerves (L1) also travel in the



**Figure 1.** Transverse section of the abdominal wall showing the path of nerves T7-T12 (left) and L1 (right) within the transversus plane

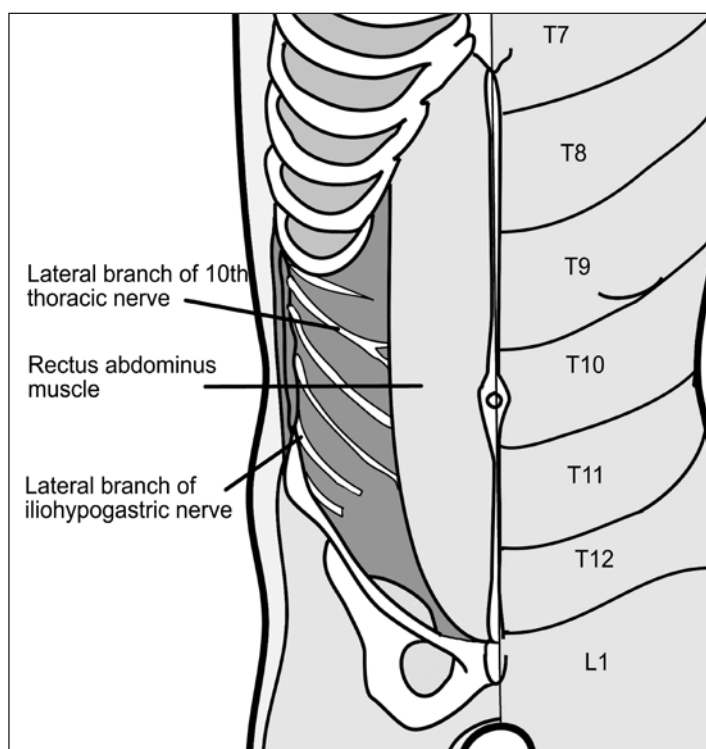
**Katrina Webster**

Senior Anaesthetic Registrar  
Royal Hobart Hospital  
Hobart  
Australia

plane between the transversus abdominis and internal oblique, innervating both of these muscles. T7-T12 continue anteriorly from the transversus plane to pierce the rectus sheath and end as anterior cutaneous nerves. The thoracic nerves, T7 to T12, provide motor innervation to pyramidalis and the rectus muscle. These nerves have cutaneous branches laterally in the abdomen. T7-T11 provide sensory innervation to the skin, costal parts of diaphragm, related parietal pleura and the peritoneum. T7 gives sensory innervation at the epigastrium, T10 at the umbilicus, and L1 at the groin.<sup>5,6</sup>

### CLINICAL APPLICATIONS

TAP block can be used for any surgery involving the lower abdominal wall. This includes bowel surgery, caesarean section, appendectomy, hernia repair, umbilical surgery and gynaecological surgery. A single injection can achieve sensory block over a wide area of the abdominal wall. The block has been shown to be useful in upper abdominal surgery,<sup>7</sup> but the upper extent of the block and its use in upper abdominal surgery are

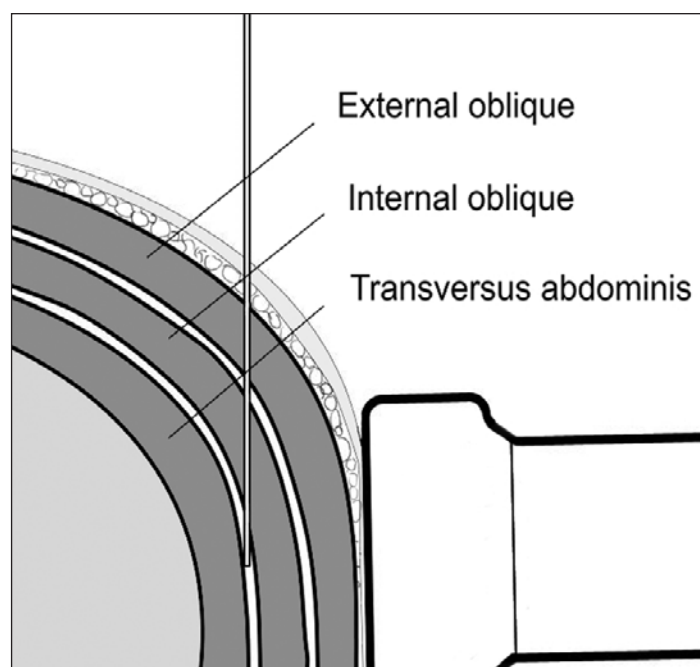


**Figure 2.** Cutaneous nerve distribution and dermatomes of the abdominal wall

controversial.<sup>8,9,10,11</sup> TAP block is particularly useful for cases when an epidural is contraindicated or refused.<sup>3</sup> The block can be performed unilaterally (eg. appendectomy), or bilaterally when the incision crosses the midline (eg. Pfannenstiel incision). A single injection can be used, or a catheter inserted for several days of analgesic benefit. TAP block also has a role as rescue analgesia on awake postoperative patients who did not receive blocks prior to abdominal surgery.<sup>12</sup>

### PERFORMING THE BLOCK

The principal of the block is to deposit local anaesthetic into the tissue plane between the internal oblique and the transversus abdominis. The two methods used include a blind technique, based on surface anatomy landmarks, and an ultrasound guided technique performed under direct vision. These methods are described below. The block takes up to 30 minutes to be effective so should be performed after induction and prior to surgery where possible. Intravenous opioid is required for skin incision and the early operative period as the block becomes established. TAP block for caesarean section is performed at the end of surgery and hence intravenous opioid will be required in the immediate post operative period while the block is becoming established.



**Figure 3.** Transverse section of the abdomen showing injectate deposition in the transversus plane

### Anaesthetic Agent

The volume of injectate is critical to success of TAP block. In an average sized adult 30ml of local anaesthetic should be used for unilateral block and 25-30ml used each side for bilateral block. Lignocaine, bupivacaine and ropivacaine have each been used for this block with success. Adequate volume is more important than using strong concentrations of local anaesthetic. The maximal safe dose of the chosen agent must be strictly adhered to. Examples of possible doses are shown in Table 1.

### Landmark Technique

The landmark for palpation is the 'triangle of Petit' which lies above the pelvic rim in the midaxillary line (see Figure 4). The

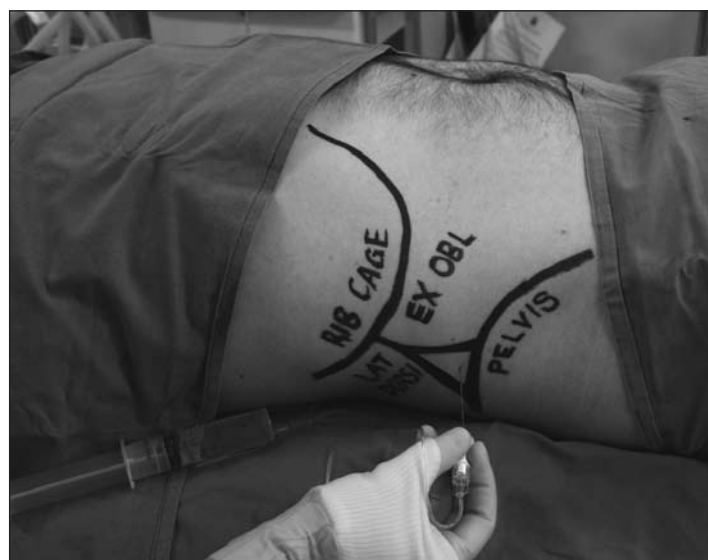**Table 1.** Examples of appropriate drug selection for unilateral and bilateral TAP block based on patient weight

	30kg	50kg	60-80kg
<i>Unilateral</i> (eg. Appendectomy, hemicolectomy)	15ml: 0.5% ropivacaine or 0.375% bupivacaine	25ml: 0.5% ropivacaine or 0.375% bupivacaine	30ml: 0.5% ropivacaine or 0.375% bupivacaine
<i>Bilateral - dose to each side</i> (eg. LSCS, abdominal hysterectomy)	15ml: 0.25% ropivacaine or 0.25% bupivacaine	25ml: 0.25% ropivacaine or 0.25% bupivacaine	30ml: 0.25% ropivacaine or 0.25% bupivacaine

inferior border of the triangle is the iliac crest. The anterior border of the triangle is formed by the lateral edge of the external oblique muscle. The posterior border of the triangle is formed by the lateral edge of the latissimus dorsi muscle.<sup>2,7,13</sup> The triangle is tender to deep palpation in conscious patients.

The puncture site is just above the iliac crest and just posterior to the midaxillary line within the triangle of petit. A 24G blunt-tipped 50mm needle is inserted perpendicular to the skin, and a give or 'pop' is felt when the needle passes through the fascial extensions of the internal oblique muscle. The needle tip is therefore between the fascial layers of the external and internal oblique. Further advancement with a second 'pop' indicates that the needle has advanced into the fascial plane above transversus abdominis and, after aspiration, 25-30ml of local anaesthetic is injected.<sup>2,7</sup> There has been some controversy about seeking one or two 'pops' during the landmark technique of TAP block. Use of a 'two pop' technique is generally advocated and is supported by the cadaveric and imaging studies published to date.<sup>14,15</sup>

The triangle of Petit can be difficult to palpate, especially in obese patients. Rafi suggests a needle insertion point 2.5cm

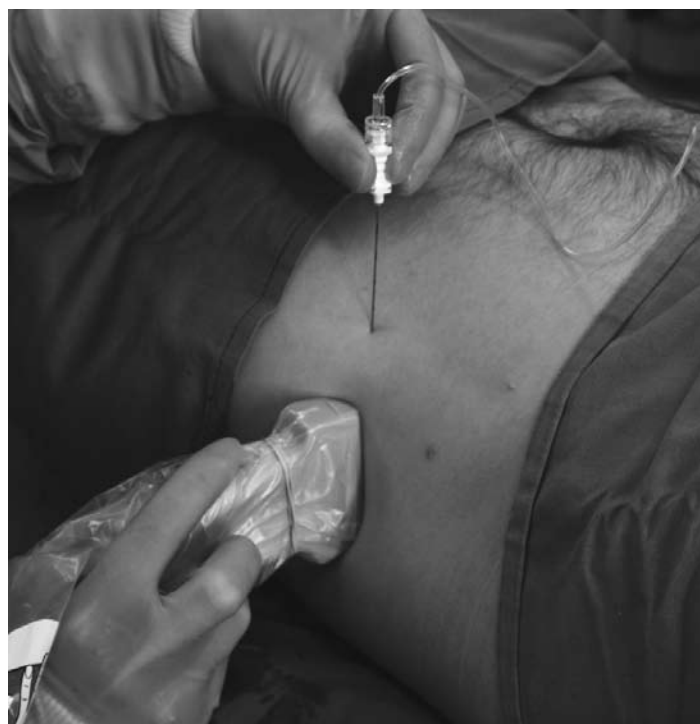

**Figure 4.** Surface anatomy labelled for landmark insertion of TAP block in an adult male in the supine position

behind the highest point of the iliac crest when the triangle is not clearly palpable.<sup>2</sup> Requesting the patient to lift his head and shoulders from the supine position will contract the abdominal muscles and can assist palpation of the triangle.

### Ultrasound Technique

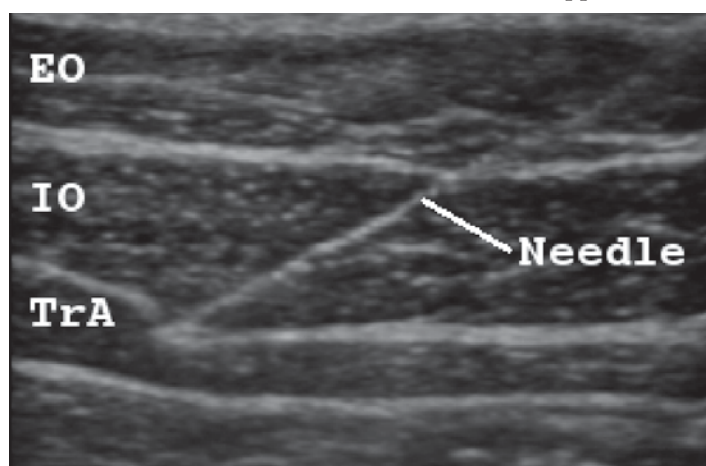
The TAP block can be performed relatively easily with the use of ultrasound. A broadband linear array probe is used, with an imaging depth of 4-6cm. The ultrasound probe is placed transverse to the abdomen (horizontal plane) in the midaxillary line between the costal margin and the iliac crest. Three muscle layers are clearly seen in the image. A 100mm short bevel needle is used. The needle is inserted in a sagittal plane approximately 3-4 cm medial to the ultrasound probe. The point of needle insertion is closer to the probe in children and further from the probe for obese adults. For optimal imaging of the needle it should be held parallel to the long



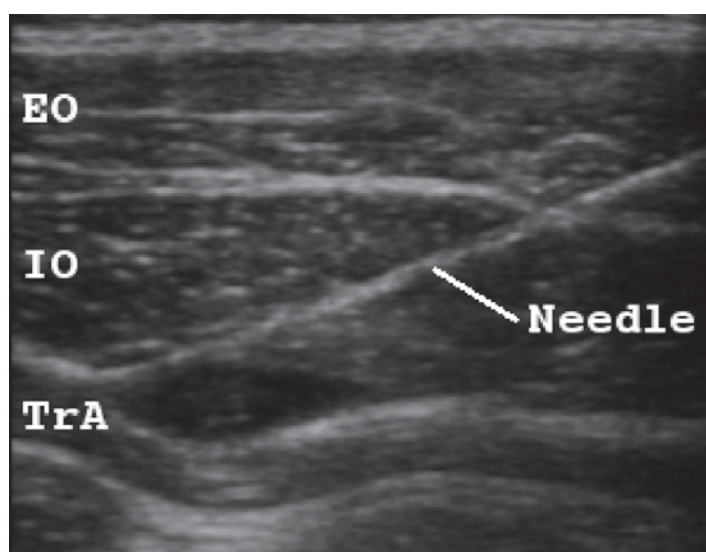
**Figure 5.** Needle and probe position for ultrasound guided TAP block in an adult male in the supine position

axis of the ultrasound probe (in plane technique). The probe is moved slightly anteriorly to image the skin puncture and superficial course, then gradually posteriorly to the midaxillary line position (shown in Figure 5), following the needle to the correct position in the transverse abdominis plane.

Real time ultrasound imaging allows observation of the needle passage through the skin and subcutaneous tissue, then through the external and internal oblique muscles. The needle tip is directed into the plane below the internal oblique and above the transversus abdominis muscle. A small volume of local anaesthetic (1ml) will be seen to open the plane between the two muscles and can be followed by insertion of the full dose of local anaesthetic. If the 1ml dose appears to be



**Figure 6.** Ultrasound image showing the muscle layers of the lateral abdominal wall with the needle seen positioned above the transversus abdominis muscle. EO: external oblique, IO: internal oblique, TrA: transversus abdominis



**Figure 7.** Ultrasound image during initial injection of 5ml local anaesthetic. Injectate is in the transversus plane and alters the muscle layer appearance. EO: external oblique, IO: internal oblique, TrA: transversus abdominis

within muscle rather than between them, needle adjustment is required. The local anaesthetic injectate appears hypoechoic (black compared to the muscle layers) on ultrasound imaging. When the needle tip is positioned correctly the injectate will be seen on ultrasound to spread out in the plane between the two muscles.<sup>3</sup> Ultrasound can also allow direct visualisation of structures in this region such as the deep iliac circumflex vessels and the iliohypogastric/ilioinguinal nerves.<sup>16,17</sup>

## AREAS OF CONTROVERSY

There is debate in the literature regarding the extent of the sensory block achieved. Published investigators agree there is reliable block spread between L1 and T10 dermatomes. Initial publications found a block height from L1 to T7 could be achieved and hence the block was suitable for use in midline laparotomy.<sup>9,11</sup> Other investigators have found that the block does not reliably rise above the umbilicus and is therefore better suited to lower abdominal surgery only.<sup>8,10</sup> McDonnell and Laffey state that examining extent of the block prior to full spread could be misleading and measurement will be most accurate, when full block height has been achieved several hours after insertion of the block.<sup>9</sup> Some investigators have found the block height does not continue to extend over hours.<sup>10</sup> It may be that a different distribution of anaesthetic (and hence sensory blockade) occurs with the landmark technique compared to ultrasound-guided technique. Further anatomic studies are in progress to examine this issue.

## EVOLVING DEVELOPMENTS IN TECHNIQUE

An alternative approach called the oblique subcostal TAP block has recently been described.<sup>10</sup> In this variation the ultrasound probe is held below and parallel to the costal margin, oblique to the sagittal plane. A 100-150mm needle is inserted at a position close to the xiphoid process and in plane to the ultrasound probe. The local anaesthetic is deposited between the transversus abdominis and rectus abdominis muscles, or between the rectus muscle and posterior rectus sheath (if there is no transversus at that level). The advantage of this approach is reliable spread of sensory block above the umbilicus (eg. for cholecystectomy).

## LITERATURE REVIEW

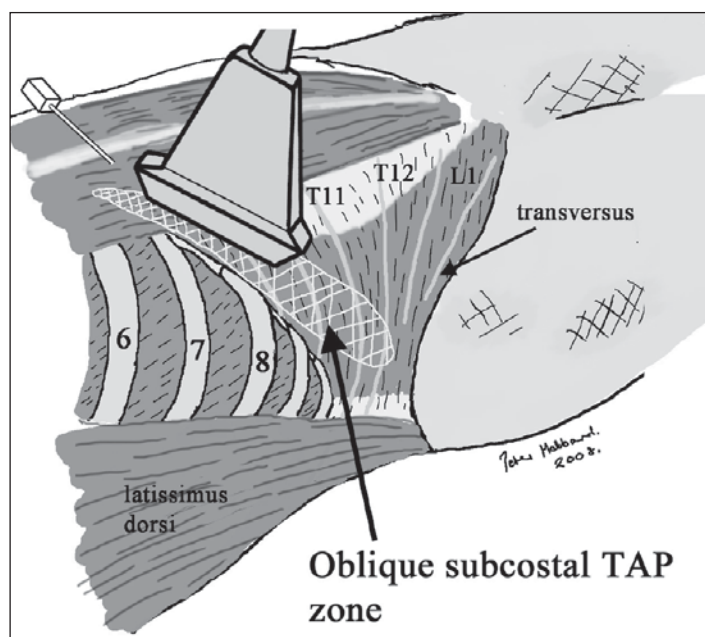
In 2004, a report was published detailing a trial of the landmark TAP block procedure performed on both cadaveric specimens (methylene blue dye was used) and on healthy volunteers (radio-opaque dye with 0.5% lignocaine was used).<sup>14</sup> Cadaveric dissection revealed dye deposition in the transversus abdominis plane. CT imaging of live volunteers identified dye in the transversus abdominis neurovascular plane and pinprick testing indicated sensory block from L1-T8 dermatome.

Another cadaveric study was published by the same team of investigators in 2007.<sup>15</sup> This examined spread of methylene

blue dye injected via the angle of Petit using the landmark technique. The cadaveric dissection revealed reliable deposition of injectate into the transversus abdominis plane. In addition three healthy male volunteers were given a TAP block with radio-opaque dye and lignocaine to a final concentration of 0.5% and final volume of 20ml. 20 minutes after the block CT imaging demonstrated spread throughout the transversus abdominis plane. Sensory block assessment revealed a block from L1 to T7 which receded over 4 to 6 hours. A further three healthy male volunteers were given a TAP block of 1% lignocaine and radiopaque dye then MRI was performed at 1, 2 and 4 hours after the block. A gradual reduction in deposition of the injectate was demonstrated over time.

A small trial of TAP blocks performed on 12 open retropericubal prostatectomy patients was reported in 2006.<sup>18</sup> The blocks were performed with 20ml of 0.375% bupivacaine to each side pre-operatively. Minimal morphine consumption was demonstrated (mean of 6.33mg at 48 hours with a range of 0-15mg). There were no adverse effects reported from the block.

In 2007, TAP block efficacy was examined in a randomised clinical trial of 32 patients undergoing large bowel resection via midline abdominal incision.<sup>7</sup> The patients were randomised to receive standard care (PCA, regular non-steroidal antiinflammatory drugs and paracetamol) or TAP block with the landmark technique (20ml 0.375% levobupivacaine). They found the TAP group had decreased visual analogue scale pain scores at emergence and at all times measured postoperatively up to 24 hours. There were no complications from the blocks



**Figure 8.** Needle and probe position for ultrasound guided oblique subcostal TAP block (reproduced with kind permission from Dr P Hebbard)

and a high reported patient satisfaction level in the TAP group.

Another randomised clinical trial from the McDonnell team in 2008 examined TAP block efficacy after caesarean section delivery.<sup>19</sup> Fifty elective patients for caesarean section (via spinal anaesthetic and Pfannenstiel incision) were randomised to receive TAP block (landmark method) versus placebo in addition to standard anaesthesia (paracetamol, diclofenac and intravenous morphine). The TAP block was performed at the end of surgery using 1.5mg/kg ropivacaine (to a maximal dose of 150mg). A blinded investigator assessed patients at specific time intervals between 2 to 48 hours postoperatively. Results showed TAP block reduced visual analogue pain scores and mean total morphine requirements in the first 48 hours (18mg versus 66mg in the placebo group). There were no complications from the blocks.

A second publication on use of TAP blocks after caesarean section describes placement of TAP catheters under ultrasound guidance in three case reports.<sup>16</sup> Continuous infusions of 0.2% ropivacaine at 4ml/h was used for 72 hours. The reported benefits of the block included low pain scores, minimal use of supplemental opioid and absence of nausea and vomiting.

A recent case report describes a complication relating to the blind landmark technique for TAP insertion.<sup>20</sup> A TAP block was performed on a woman for abdominal hysterectomy (50kg in weight and 160cm tall). At laparotomy, approximately 50ml of fresh blood was found in the abdomen, due to needle perforation of the liver. The liver was found to be enlarged and reached the right iliac crest. Authors of the report recommend palpation of the liver edge prior to block insertion, especially in people of small stature.

## DANGERS AND LIMITATIONS

Regional anaesthesia in general has a very low rate of serious complications. The risk in regional anaesthesia varies with the type and location of the block. The head and neck for example, are sites of higher complication rates compared to the abdomen. General risks of regional blockade include: needle trauma, intraneural injection, neural ischaemia, inadvertent intravascular injection, local anaesthetic toxicity, infection, and poor/failed block.<sup>17</sup> The general risks for regional blockade are applicable to the TAP block, however the site of injection for the TAP block is relatively low risk. This review found only one published report of complication from the TAP landmark technique (as already described)<sup>20</sup> and could not identify any published cases of complications from the ultrasound-guided TAP block.

The landmark technique relies on the 'pop' sensation which some clinicians believe is an imprecise sign.<sup>3</sup> The identification

of the landmarks is more challenging in the obese hence the risk of peritoneal perforation is probably higher. If anatomy is abnormal, such as hepatomegaly, there is risk of damage from the needle puncture. Ultrasound techniques are likely to improve the safety of this block as the needle passage and injection can be followed in real time, however this has not been scientifically tested to date. Some authors argue that peritoneal perforation with a small gauge sterile needle is not likely to be significant.<sup>21</sup>

## FUTURE DEVELOPMENTS

Ultrasound guidance for performance of this block has become the method of choice where available. We can look forward to further data being published on effects of the block and likely a wider range of possible techniques, particularly for targeting the upper abdominal wall. The ease with which this block can be performed, an excellent safety profile to date, and outstanding clinical utility, will no doubt lead to increasing popularity and use of the transversus abdominis plane block.

## ACKNOWLEDGEMENTS

The author would like to thank the Regional Anaesthesia Specialists with whom aspects of the content of this article have been discussed: Dr P Hebbard, Dr J Laffey, Dr M Grayling and Dr A Grice. Thank you to Dave Wilkinson for producing Figures 1,2 and 3.

## REFERENCES

1. Atkinson R, Rushman G, Lee J. A synopsis of anaesthesia, 10th ed. Bristol: Wright, 1987: 637-640.
2. Rafi A. Abdominal field block: a new approach via the lumbar triangle. *Anaesthesia* 2001; **56**: 1024-26.
3. Hebbard P, Fujiwara Y, Shibata Y, Royle C. Ultrasound-guided transversus abdominis plane (TAP) block. *Anaesthesia and Intensive Care* 2007; **35**: 616-7.
4. Hebbard P. 2007; Website: [www.heartweb.com.au/downloads/TAPblock.pdf](http://www.heartweb.com.au/downloads/TAPblock.pdf)
5. Moore K, Dalley A. Clinically oriented anatomy. 5th ed. Philadelphia. Lippincott Williams & Wilkins. 2006: 206.
6. Snell R. Clinical anatomy. 8th ed. Baltimore. Lippincott Williams & Wilkins. 2008.
7. McDonnell J, O'Donnell B, Curley G, Heffernan A, Power C, Laffey J. The Analgesic Efficacy of Transversus Abdominis Plane Block After Abdominal Surgery: A Prospective Randomized Controlled Trial. *Anaesthesia and Analgesia* 2007; **104**: 193-7.
8. Shibata Y, Sato Y, Fujiwara Y, Komatsu T. Transversus Abdominis Plane Block. *Anesthesia and Analgesia* 2007; **105**: 883.
9. McDonnell J, Laffey J. Transversus Abdominis Plane Block. *Anesthesia and Analgesia* 2007; **105**: 883.
10. Hebbard P. Subcostal transversus abdominis plane block under ultrasound guidance. *Anaesthesia and Analgesia* 2008; **106**: 674-5.
11. Laffey J, McDonnell J. Subcostal Transversus Abdominis Plane Block Under Ultrasound Guidance. *Anesthesia and Analgesia* 2008; **106**: 675.
12. Hebbard P. Audit of "rescue" analgesia using TAP block. *Anaesthesia and Intensive Care* 2007; **35**: 617-8.
13. McDonnell J, Laffey J. The Transversus Abdominis Plane Block. *Anesthesia and Analgesia* 2007; **105**: 282-3.
14. McDonnell J, O'Donnell B, Tuite D, Farrell T, Power C. The regional abdominal field infiltration (R.A.F.I.) technique: computerized tomographic and anatomical identification of a novel approach to the transversus abdominis neuro-vascular fascial plane *Anesthesiology* 2004; **101**: A899.
15. McDonnell J, O'Donnell B, Farrell T, Gough N, Tuite D, Power C, Laffey J. Transversus Abdominis Plane Block: A Cadaveric and Radiological Evaluation. *Regional Anesthesia and Pain Medicine* 2007; **32**: 399-404.
16. Gucev G, Yasui G, Chang T, Lee J. Bilateral Ultrasound-Guided Continuous Ilioinguinal-Iliohypogastric Block for Pain Relief After Cesarean Delivery. *Anesthesia and Analgesia* 2008; **106**: 1220-2.
17. Hadzic A. Textbook of regional anaesthesia and acute pain management. 1st ed. New York. McGraw-Hill. 2007: **8**, 691.
18. O'Donnell B. The transversus abdominis plane (TAP) block in open retropubic prostatectomy. *Regional anaesthesia and pain medicine* 2006; **31**: 91.
19. McDonnell J, Curley G, Carney J, Benton A, Costello J, Maharaj C, Laffey J. The Analgesic Efficacy of Transversus Abdominis Plane Block After Cesarean Delivery: A Randomized Controlled Trial. *Anesthesia and Analgesia* 2008; **106**: 186-91.
20. Farooq M, Carey M. A Case of Liver Trauma With a Blunt Regional Anesthesia Needle While Performing Transversus Abdominis Plane Block *Regional Anesthesia and Pain Medicine* 2008; **33**: 274-5.
21. McLeod G. Techniques of regional anaesthesia. Synopsis of anaesthesia (13th ed). Edited by Davies N and Cashman J. Philadelphia: Elsevier/Butterworth Heinemann, 2005: 454.