

Ultrasound guided rectus sheath block - analgesia for abdominal surgery

Katrina Webster

Correspondence Email: katrina.webster@dhhs.tas.gov.au

Summary

Regional anaesthesia techniques are evolving rapidly, with ultrasound technology allowing improvements in reliability and efficacy. Over recent years there has been growing interest in abdominal plane blocks, with promising data emerging on the therapeutic benefits of these techniques. The rectus sheath block is a very useful regional technique which allows sensory blockade of the abdominal wall.

HISTORY OF THE RECTUS SHEATH BLOCK

Abdominal field block was first described in 1899 by Schleich.¹ Various methods of abdominal field block have been used in anaesthetic practice over recent decades. A technique involving multiple injections of local anaesthetic in the abdominal wall was used in the 1980's.² This technique was simplified with a single injection non-ultrasound technique used through the 1990's, which was commonly used for paediatric umbilical surgery.³ Since 2007 the technique has further developed to include ultrasound guidance⁴ and placement of rectus sheath catheters.

Ultrasound guidance for regional anaesthesia is associated with higher block success rates, shorter onset times, reduced total anaesthetic dose required and reduced complications.^{5,6} There is also the advantage of direct observation of pattern of anaesthetic spread. Increasing use of ultrasound by the anaesthetic profession, and our evolving appreciation of the benefits of ultrasound in performance of regional

techniques has caused some techniques to gain new clinical utility. The rectus sheath block is an example of this evolution, where ultrasound allows accurate placement of catheters and therefore continuous ongoing postoperative analgesia becomes possible.

ANATOMY

Innervation of the anterolateral abdominal wall arises from the anterior rami of spinal nerves T7 to L1. Branches from the anterior rami include the intercostal nerves (T7-T11), the subcostal nerve (T12) and the iliohypogastric / ilioinguinal nerves (L1).

Intercostal nerves T7 to T11 exit the intercostal spaces and run in the neurovascular plane between the internal oblique and the transversus abdominis muscles. The subcostal nerve (T12) and the ilioinguinal/ iliohypogastric nerves (L1) also travel in the plane between the transversus abdominis and internal oblique, innervating both these muscles. The T7-T12 nerves continue anteriorly from the transversus plane

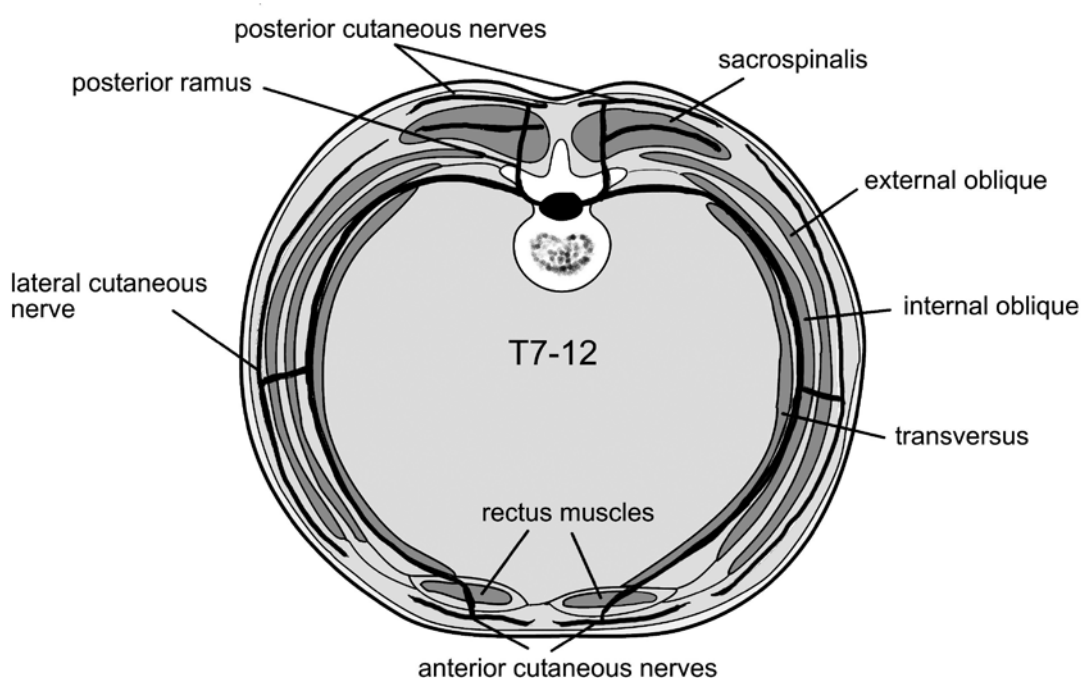


Figure 1. Transverse section of the abdominal wall showing the path of nerves T7-T12 as they travel from the spine to the anterior abdomen

Katrina Webster

Senior Anaesthetic Registrar
Royal Hobart Hospital

Hobart
Australia

to pierce the rectus sheath and end as anterior cutaneous nerves. The T7-T11 nerves provide sensory innervation to the rectus muscle and overlying skin. T7 gives sensory innervation at the epigastrium, T10 at the umbilicus, and L1 at the groin.^{7,8}

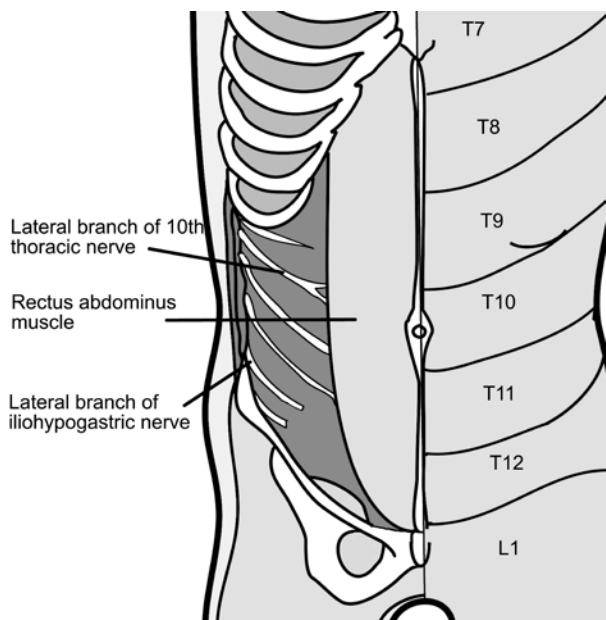


Figure 2. Cutaneous sensory nerve distribution and dermatomes on the abdominal wall

CLINICAL APPLICATIONS

Local anaesthetic deposition within the posterior rectus sheath bilaterally provides dense and predictable analgesia over the middle anterior wall from the xiphoid process to the symphysis pubis, as shown in Figure 3. It is therefore used for surgery with midline (or paramedian) abdominal incision. Rectus sheath block does not provide analgesia for the lateral abdomen.

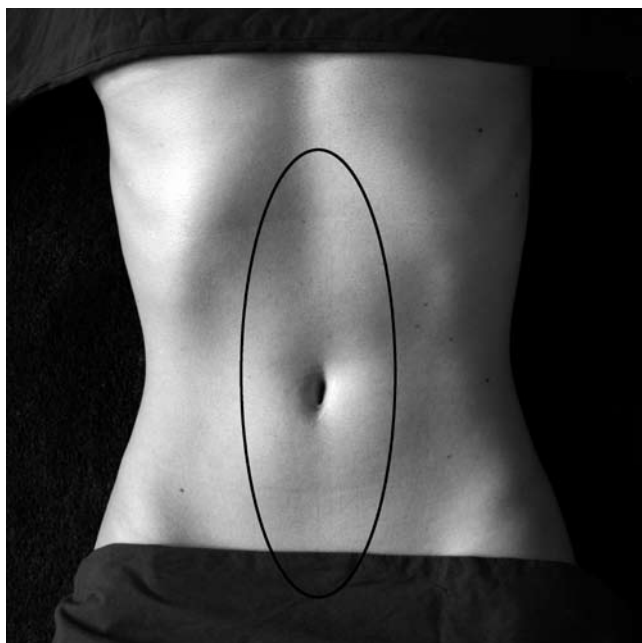


Figure 3. Area of sensory block provided by rectus sheath catheters (area within the black circle)

Rectus sheath block will provide somatic pain relief for abdominal wall structures superficial to the peritoneum. For surgery deep to the peritoneum (such as bowel resection) there is usually a component of deeper visceral pain, for which systemic analgesia is routinely given. If oral intake is permitted postoperatively a suitable analgesic regime is: regular paracetamol, regular non steroidal antiinflammatory, and oral opiate as required. If the patient remains nil by mouth postoperatively an opiate patient controlled intravenous analgesia device (PCA) can be used.

Patients with rectus sheath catheters typically demonstrate low pain scores and low opiate requirements,^{9,10} although precise benefits have yet to be well defined scientifically. It is not uncommon for patients to use no opioid medication even on day 1 after major laparotomy.

Early mobility is a major advantage of the rectus sheath catheter technique. Excellent analgesia combined with no motor block of the limbs and no mandatory connection to infusion devices or IV poles, allows patients to mobilise early. It is common to see rectus sheath catheter patients walking within 48 hours of major laparotomy. This suggests major clinical benefits including potential for reduced deep vein thrombosis and pulmonary embolus, reduced atelectasis and respiratory infection, and minimal motor deconditioning.

How does analgesic effect of rectus sheath block compare to epidural anaesthesia for abdominal surgery?

An effective epidural will provide complete analgesia after abdominal surgery, while rectus sheath block patients may experience some visceral pain. Visceral pain is usually minimal by 24 hours after surgery.

Rectus sheath catheters provide several advantages over epidural anaesthesia. These include avoidance of the significant risks associated with neuraxial techniques, especially in the setting of coagulopathy or recent use of drugs impacting upon coagulation (aspirin, clopidogrel, heparin etc). Rectus sheath catheter insertion presents minimal risk in septic patients. Sepsis is a common contraindication to epidural in emergency laparotomy patients. There is no safety disadvantage with rectus sheath catheter insertion during anaesthesia compared to awake, hence avoiding patient discomfort or distress which can occur during epidural insertion. Rectus sheath analgesia has no haemodynamic effects, and is ideal for patients with hypotension related to sepsis or hypovolaemia. Unlike epidurals, rectus sheath catheters do not need to be connected to pumps and poles thereby permitting early mobilisation.

What is the difference between rectus sheath block and transversus abdominis plane (TAP) block?

Transversus abdominis plane (TAP) block is an alternative technique for abdominal wall analgesia. The TAP block is performed laterally on the abdomen by placing local anaesthetic in the plane between the internal oblique and transversus abdominis muscles.¹¹ The distribution of sensory blockade is different to that seen with rectus sheath block (Figure 4).

Rectus sheath block reliably provides sensory block for the whole midline of the abdomen. Compared to TAP block, the rectus sheath continuous catheter technique provides denser analgesia of a much

shorter duration. For this reason rectus sheath block is only useful after laparotomy if catheters are placed and regular ongoing dosing is given into the rectus plane. In contrast, single injection TAP block has been shown in numerous studies to have ongoing reduction in pain scores and opiate consumption for several days postoperatively and so is suitable for single shot blockade.^{12,13}

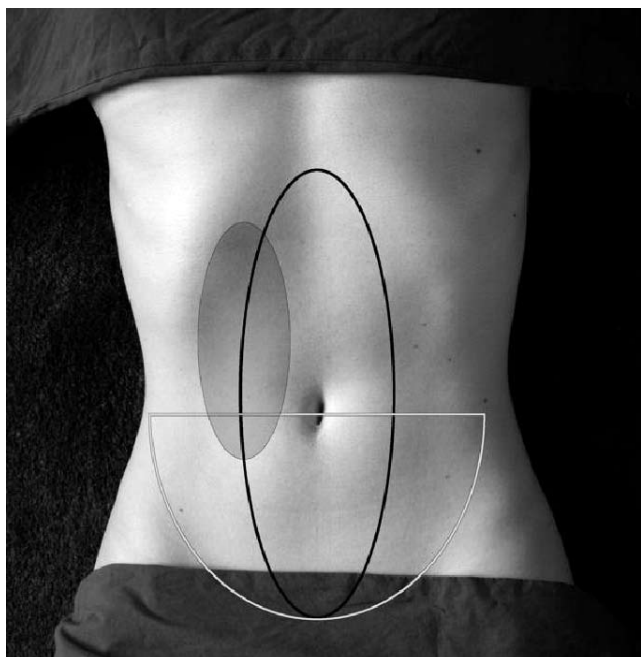


Figure 4. Comparison of sensory block achieved by rectus sheath block (large black circle over abdominal midline), bilateral standard TAP block (grey semi-circle over lower abdomen), and unilateral oblique subcostal TAP block (which can vary but approximately covers the area shaded in grey in the upper abdominal quadrant)

When do I use a rectus sheath block? When do I use a TAP block?

For midline or paramedian incision extending above the umbilicus my technique of choice is rectus sheath catheters. Median incision requires bilateral catheters while paramedian incision (over a single rectus muscle) requires a unilateral rectus sheath catheter on the surgical side. For transverse or pfannensteil incisions below the umbilicus I use a standard TAP block. For transverse or Kocher incision above the umbilicus I use an oblique subcostal TAP block.¹⁴ If a transverse incision is above the umbilicus and includes both rectus sheath and TAP territory, a combination of both techniques can be used. Care must be taken to ensure safe doses of anaesthetic are not exceeded, especially if using combined techniques.

Rectus sheath catheters in intensive care patients

Critical care patients present a particular challenge for provision analgesia after laparotomy. This patient group often require emergency surgery and may have sepsis, coagulopathy and haemodynamic instability. In many patients for urgent laparotomy an epidural is contraindicated. Siting an epidural postoperatively is usually not possible due to difficulty positioning and safety concerns placing epidurals in unconscious patients. Use of epidural analgesia after bowel surgery has caused some concern regarding decreases in splanchnic blood supply and hypoperfusion of bowel anastomoses.¹⁵ Opiate infusions can exacerbate ileus and cause

sedation. Rectus sheath catheters are an excellent analgesic modality for post laparotomy intensive care patients as they can be placed with minimal risk of complications and the resultant analgesia (without side effects) allows timely wean of sedation and extubation.¹⁰

PERFORMING THE BLOCK

Preparation

Informed consent for the chosen regional technique must be obtained for all elective cases. For patients requiring emergency laparotomy, professional judgement should be used regarding risk and benefit of placing catheters. Patients may be awake, sedated or anaesthetised. The block is ideally performed after induction and intubation but before surgical incision. If the surgery may involve the rectus muscle (such as fashioning a stoma or for paramedian incision) or immediate surgical commencement is required, the block is performed after completion of surgery prior to emergence. In the case of rescue blocks (performed on awake patients postoperatively), local anaesthetic is used to cover needle insertion and minimal or no discomfort is reported during the procedure.

A functioning intravenous cannula must be in place prior to the procedure. Vital sign monitoring, according to local guidelines, must be used during the procedure and emergency equipment to respond to complications such as local anaesthetic toxicity must be readily available.

The usual methods to ensure asepsis are adopted including sterile gown, sterile gloves and sterile drapes. A mask and hair cover should be worn. A sterile ultrasound probe cover and sterile ultrasound gel are used.

The rectus muscle is imaged with the ultrasound probe in a longitudinal orientation above the level of the umbilicus with the patient supine. A broadband (5-12MHz) linear array probe is used, with an imaging depth of 4-6cm. A 50mm probe footprint is ideal for abdominal blocks, allowing better needle imaging than smaller probes.

Inserting the needle and catheter

An 18G Tuohy needle is introduced in plane to the ultrasound probe just below the costal margin at an angle of approximately 45 degrees to the skin (see Figure 5 & 6).

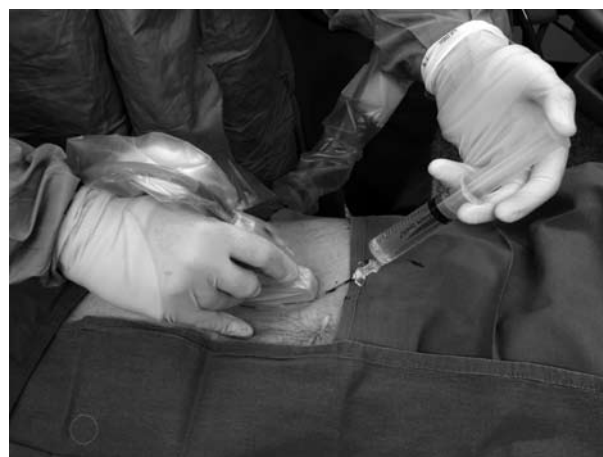

Figure 5. Position of probe and needle for rectus sheath catheter insertion

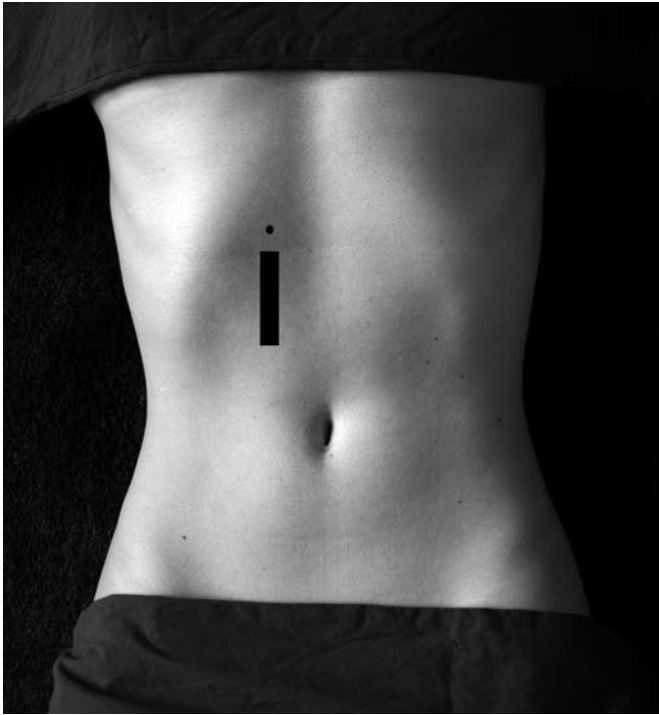

Figure 6. Representation of where probe (black rectangle) and needle (black circle) are positioned for insertion of rectus sheath catheters

The ultrasound image allows identification of the rectus muscle and hyperechoic twin lines deep to it (posterior rectus sheath and fascia transversalis). Under direct vision the needle tip is advanced to the desired position, posterior to the rectus muscle and above the underlying rectus sheath (Figures 7 and 8). Insertion of local anaesthetic will hydrodissect the rectus muscle away from the posterior rectus sheath.

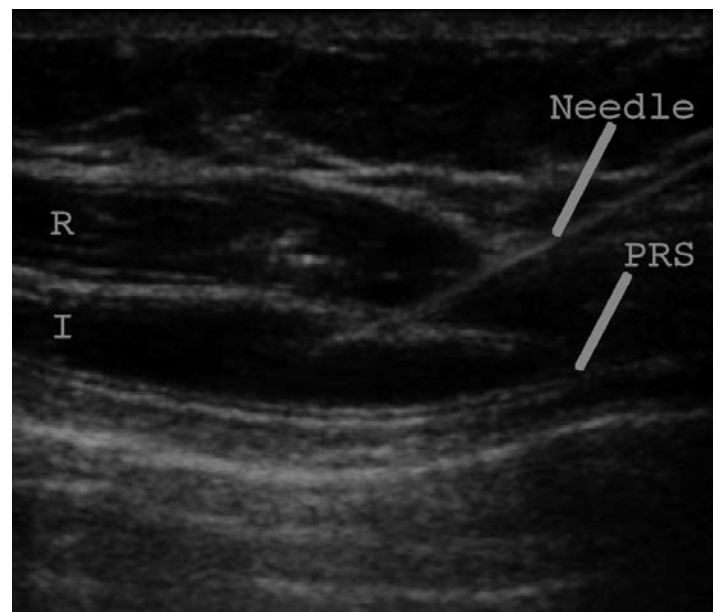
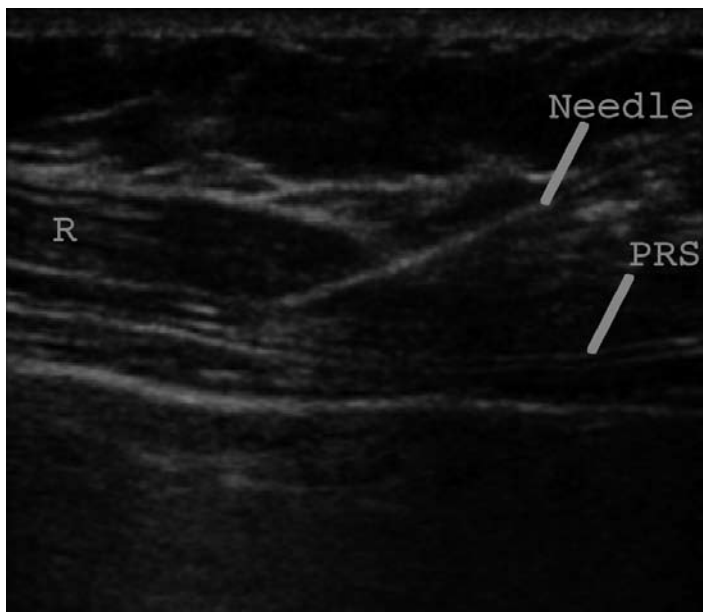


Figure 7. The first ultrasound image shows a needle with the needle tip positioned below the rectus muscle. The second ultrasound image is 1 second later as local anaesthetic is injected to lift the rectus muscle off the posterior rectus sheath. R= rectus muscle, I= injectate (local anaesthetic), PRS= posterior rectus sheath (twin 'tram'-lines).

A 20ml bolus dose of 0.25% bupivacaine or levobupivacaine (or 0.375% ropivacaine) is deposited, with ultrasound imaging demonstrating correct location. The catheter is then threaded through the Tuohy needle and secured to the skin. Approximately 8cm of catheter is inserted into the space. Depending on the angle of needle insertion and size of the patient, the catheter depth at the skin is usually 12-15cm. With an insertion point just below the costal margin this should position the tip of the catheter at approximately the umbilical level. It is useful to ensure the dressing stays as high and as lateral on the abdomen as possible to avoid interference with the surgical field (Figure 9).

The technique is repeated on the opposite side. Further doses of 15-20ml bupivacaine or levobupivacaine 0.25% (or ropivacaine 0.375%) are given to each catheter as a slow injection every 6 hours.

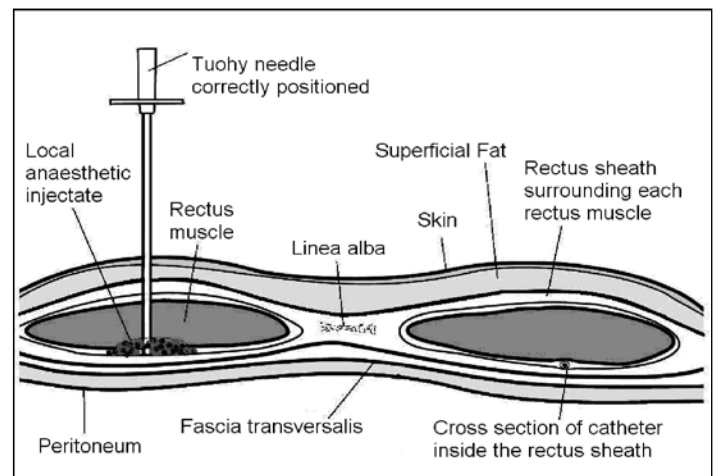


Figure 8. Transverse section of the anterior abdominal wall, with depiction of Tuohy needle position and location of local anaesthetic injectate for rectus sheath block

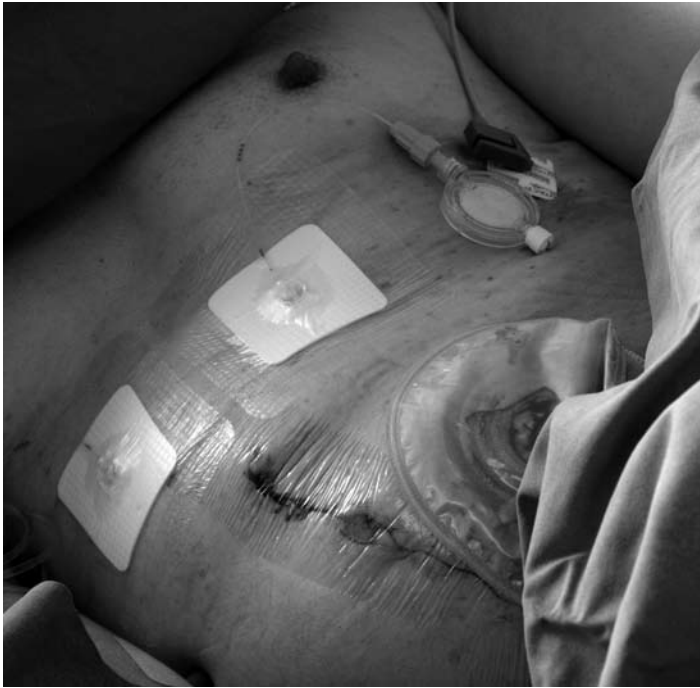

Figure 9. Bilateral rectus sheath catheters in situ postoperatively

LOCAL ANAESTHETIC AGENT AND DURATION OF ACTION

0.25% bupivacaine/levobupivacaine or 0.375% ropivacaine as a 20ml bolus every 6 hours will provide effective continuous analgesia. This concentration and volume of local anaesthetic will provide a sensory block lasting 5-7 hours. Patients often notice the block is less effective in the hour before the next dose is due. My experience of lower doses or lower concentrations (such as 0.2% ropivacaine) has been that the block duration is reduced, which may be a logistical disadvantage requiring more frequent dosing.

ULTRASOUND VERSUS SURGICAL PLACEMENT OF RECTUS SHEATH CATHETERS

Surgical insertion of rectus sheath catheters intraoperatively was described in 2007.⁹ Surgically placed catheters are an efficient use of time and have the advantage of placement under direct vision of the rectus muscle. Disadvantages of placement via the abdominal cavity include potential soiling of a sterile rectus compartment (when forceps and Tuohy needle open the posterior rectus sheath through the peritoneum), and that the subsequent hole created can cause leakage of anaesthetic agent from the rectus sheath space into the abdominal cavity with resultant loss of block efficacy.

Ultrasound placement via the anterior abdominal wall allows the posterior sheath to remain intact, avoiding leakage of local anaesthetic and protects the sterility of the rectus sheath compartment. Preincision placement of the catheters via the abdominal wall achieves intraoperative analgesia and minimises sympathetic response to the surgical procedure.

DANGERS AND LIMITATIONS

Any regional technique carries a risk of introducing infection, causing bleeding or damaging local structures. It is important to be aware that

the superior and inferior epigastric vessels run in the posterior rectus sheath and there is the potential to place the catheter or needle tip within these vessels. Intravascular administration of local anaesthetic may inadvertently occur with catastrophic consequences. Rectus sheath haematoma can occur if the epigastric vessels are damaged.

If sonoanatomy is not recognised correctly or needle position is not followed accurately with ultrasound, it is possible to puncture the posterior rectus sheath, peritoneum and bowel. Use of ultrasound technology for rectus sheath block has reduced this risk considerably.¹⁶

The superficial position of rectus sheath catheters and the distance from major nerves or major blood vessels is important in considering safety of the technique. If infection or haematoma were to occur from this technique the implications would be much less serious than would be the case with similar complications in the epidural space.

If rectus sheath catheters are given manual intermittent dosing there is increased risk of introducing infection (as the sterile system is frequently accessed). There is also a risk of serious drug error if 20ml of local anaesthetic is administered via an incorrect route, such as intravenously. These concerns may be overcome by use of a mechanical intermittent dosing device, which is connected continuously to the catheter system. This removes risk of contamination or human error with anaesthetic dosing. The disadvantage of this strategy is that extra equipment is then connected to the patient and some advantages of easy early mobilisation may be lost.

To date there have been no reported complication from ultrasound guided placement of rectus sheath catheters. Attention to strict aseptic technique, careful ultrasound guidance and vigilance to signs of intravascular placement will minimise the risks of this technique.

FUTURE DEVELOPMENTS

Clinical use of rectus sheath catheters is increasing at a rapid pace. For some anaesthetists, this technique is already routine practice for elective laparotomy. Rectus sheath catheters are very useful for emergency laparotomy, especially when epidural is contraindicated. The significant benefits in the intensive care setting after abdominal surgery are leading to increasing use for this patient group.

While anecdotal evidence to date is very encouraging, anaesthetists await quantitative data to evaluate safety and efficacy of this technique. Numerous clinical trials are currently in progress to examine the rectus sheath catheter technique.

CONCLUSION

Rectus sheath catheters are an emerging anaesthetic technique providing excellent analgesia after laparotomy. The anatomic characteristics of this block suggest minimal serious complications are likely, and this regional block is particularly useful where epidural is contraindicated. When use of ultrasound for abdominal wall imaging is familiar, this technique is very easy to learn. The excellent safety profile to date, and superb clinical utility of this technique will ensure that popularity of rectus sheath catheters for abdominal surgery will continue to grow.

ACKNOWLEDGEMENTS

I would like to acknowledge Royal Devon and Exeter NHS Staff Specialists Dr Alex Grice and Dr Matt Grayling for their education in the field of regional anaesthesia. Figure 1 & 2 by D Wilkinson, Figure 3, 4 and 6 by K Webster & D Sutton, Figure 8 by D Wilkinson & K Webster.

REFERENCES

1. Schleich CL. *Schmerzlose Operationen*. Berlin: Springer; 1899: 240-1.
2. Atkinson R, Rushman G, Lee J. *A synopsis of anaesthesia*. 10th ed. Bristol: Wright; 1987: 637-40.
3. Annadurai S, Roberts S. Peripheral and local anaesthetic techniques for paediatric surgery. *Anaesthesia and Intensive Care Medicine* 2007; **8**: 189-93.
4. Sandeman DJ, Dilley AV. Ultrasound-guided rectus sheath block and catheter placement. *ANZ Journal of Surgery* 2008; **78**: 621-3.
5. Marhofer P, Greher M, Kapral S. Ultrasound guidance in regional anaesthesia. *Br J Anaesth* 2005; **94**: 7-17.
6. Sites BD, Brull R. Ultrasound guidance in peripheral regional anaesthesia: philosophy, evidence-based medicine, and techniques. *Current Opinion in Anaesthesiology* 2006; **19**: 630-9.
7. Moore K, Dalley A. *Clinically oriented anatomy*. 5th ed. Philadelphia: Lippincott Williams & Wilkins; 2006: 206.
8. Snell R. *Clinical anatomy*. 8th ed. Baltimore: Lippincott Williams & Wilkins; 2008.
9. Cornish P, Deacon A. Rectus sheath catheters for continuous analgesia after upper abdominal surgery. *ANZ Journal of Surgery* 2007; **77**: 84.
10. Webster, K, Hubble, S. Rectus sheath analgesia in intensive care patients: technique description and case series. *Anaesthesia and Intensive Care* 2009; **37**: 855.
11. Webster K. The transversus abdominis plane (TAP) block: abdominal plane regional anaesthesia. *Update in anaesthesia* 2008; **24,1**: 24-9.
12. O'Donnell BD, McDonnell JG, McShane AJ. The transversus abdominis plane (TAP) block in open retropubic prostatectomy. *Regional Anesthesia and Pain Medicine* 2006; **31**: 91.
13. McDonnell JG, O'Donnell B, Curley G et al. The analgesic efficacy of transversus abdominis plane block after abdominal surgery: a prospective randomized controlled trial. *Anesth Analg* 2007; **104**: 193-7.
14. Hebbard P. Subcostal transversus abdominis plane block under ultrasound guidance. *Anesth Analg* 2008; **106**: 674-5; author reply 675.
15. Gould TH, Grace K, Thorne G, Thomas M. Effect of thoracic epidural anaesthesia on colonic blood flow. *Br J Anaesth* 2002; **89**: 446-51.
16. Dolan J, Lucie P, Geary T, Smith M, Kenny G. The rectus sheath block for laparoscopic surgery in adults: a comparison between the loss of resistance and ultrasound guided techniques. *Anaesthesia* 2007; **62**: 302.