

## Tracheostomy

Rakesh Bhandary and Niraj Niranjn  
Correspondence Email: [docrakesh2001@gmail.com](mailto:docrakesh2001@gmail.com)

### INTRODUCTION

Tracheotomy refers to the surgical opening of the trachea, while tracheostomy refers to the creation of a stoma at the skin surface, which leads to the trachea. Tracheostomies may be temporary or permanent. A temporary tracheostomy may be used as a permanent tracheostomy, however there will still be a communication between the pharynx and the lower airway via the larynx.

### INDICATIONS FOR TRACHEOSTOMY

#### Upper airway obstruction

This is no longer the most common indication for tracheostomy, owing to the improvement in designs of intubating laryngoscopes and alternative management strategies. Upper airway obstruction may be caused by swelling resulting from burns, anaphylaxis, trauma or infection or as a direct result of facial trauma or fractures.

#### Prolonged ventilation

This is now the most common indication for tracheostomy, certainly in the intensive care setting. A tracheostomy is a more secure airway and decreases dead space, which facilitates weaning from ventilation. The timing of tracheostomy for this purpose is still controversial (see later).

#### To provide pulmonary toilet and/or to protect the airway.

Tracheostomies may sometimes be performed for conditions associated with excessive tracheo-bronchial secretions requiring regular secretion clearance by suction. Examples are bulbar palsy, infections or neurological conditions where cough and swallow are impaired.

Tracheostomy may also be indicated as part of another procedure, for example, head and neck surgery.

### EFFECTS OF A TRACHEOSTOMY

- The larynx is bypassed and so the patient is unable to speak.
- There is decreased anatomical and respiratory dead space, decreasing the work of breathing.

- There is loss of humidification and filtration function by the nasal mucosa.
- There is an increased risk of respiratory tract infection.
- There is a redundant area above tracheal opening and below the larynx in which mucus can accumulate and fall back into the lungs.
- A foreign body reaction can occur, causing local inflammation.

### TIMING OF TRACHEOSTOMY IN CASES OF PROLONGED VENTILATION

The timing of tracheostomy remains an issue of debate. In a study of tracheostomy in mechanically ventilated adult ICU patients, Terragni et al found no statistically significant difference in the rates of ventilator-associated pneumonia with early tracheostomy (after 6-8 days of laryngeal intubation) versus late tracheostomy (after 13-15 days of laryngeal intubation).<sup>1</sup>

Meanwhile a large, retrospective cohort analysis including nearly 11,000 critically ill patients evaluated the impact of tracheostomy timing on mortality. The authors found a slight overall improvement in survival in patients who underwent tracheostomy within the first 10 days of intubation.<sup>2</sup>

**The TracMan study** was carried out in the United Kingdom to assess the impact of early (day 1-4 of ICU admission) versus late (day 10 or later) tracheostomy.<sup>3</sup> The study included 909 patients from 87 UK hospitals who were expected to stay 7 days or more in the ICU, between March 2006 and December 2008. Patients were randomised to early (n=455) or late (n=454) tracheostomy. Patient characteristics were similar across both groups, with respiratory failure the most common cause of admission to the ICU.

There was no significant difference in mortality between the early and late tracheostomy groups at 30 days (139 versus 141 deaths) or at 2 years post randomisation, with a 74% follow up rate. There was also no significant difference in ICU or hospital length of stay and no significant difference in antibiotic use. However, mean days of sedation were predictably reduced - to 6.6 days in the early group, compared with 9.3 days in the late group.

### Summary

This article describes the indications for this relatively common ICU procedure. It is of particular importance that ICU staff know how to manage airway emergencies in patients with tracheostomy. An example of a management algorithm is included.

**Rakesh Bhandary**  
Royal Victoria Infirmary  
Newcastle upon Tyne  
UK

**Niraj Niranjn**  
University Hospital of North  
Durham  
UK


At the study's presentation, at the 29th International Symposium of Intensive Care and Emergency Medicine, the lead author stated the following: "If you had 100 patients requiring tracheostomy, doing it early results in 2.4 days less sedation overall, but you would perform 48 more, with 3 more procedural complications and no effect on mortality or ICU length of stay."

### TECHNIQUES FOR INSERTION

Tracheostomy may be performed using a percutaneous or an open surgical technique.

Percutaneous tracheostomies are performed by anaesthesiologists or intensivists, usually under fiberoptic bronchoscopic guidance. Open surgical tracheostomies are performed by ENT surgeons and in some countries, trauma surgeons. Percutaneous tracheostomy was first described in the late 1950s and 1960s, but received widespread acceptance following introduction of commercial kits.

Two initial techniques were described – a serial dilatational technique described by Ciaglia et al in 1954 and a guidewire dilating forceps (GWDF) method described by Griggs and colleagues in 1990. In 2000, Byhahn et al modified the Ciaglia technique by introducing the 'Blue Rhino'.<sup>5</sup> This hydrophilically coated, curved dilator allows progressive dilatation of the tracheal stoma in a single step, reducing the risk of posterior tracheal wall injury, intraoperative bleeding and the adverse effect on oxygenation during repeated airway obstruction by sequential dilators.



**Figure 1.** The Blue Rhino single stage dilator (Cook Medical).

### Percutaneous tracheostomy insertion

Many commercial kits are available but they all employ a Seldinger guidewire technique for tracheostomy tube insertion. Techniques may vary slightly, depending upon operator preference and experience. A full description of this technique is beyond the scope of this article.

### CAUTIONS AND RELATIVE CONTRAINDICATIONS FOR PERCUTANEOUS TRACHEOSTOMY<sup>6</sup>

The relative contraindications are subject to the experience and clinical judgement of the operator and are not set in stone.

#### Box 1. Contraindications to percutaneous tracheostomy

##### Emergency airway access (cricothyroidotomy preferred)

##### Difficult anatomy

- Morbid obesity with short neck
- Limited neck movement
- Cervical spine injury – suspected or otherwise
- Aberrant blood vessels
- Thyroid or tracheal pathology

##### Moderate coagulopathy

- Prothrombin time or activated partial thromboplastin time greater than 1.5 times the reference range
- Platelet count less than 50 000 per mL

##### Significant gas exchange problems

e.g. PEEP > 10cmH<sub>2</sub>O or FIO<sub>2</sub> greater than 0.6

**Evidence of infection** in the soft tissues of the neck at the insertion site

##### Age less than 12 years

### CARE OF THE TRACHEOSTOMY

#### Changing tracheostomy tubes

While changing a tracheostomy tube can be hazardous, failing to change one when required also carries risks. Guidance from the Intensive Care Society points out that recommendation regarding the timing of tube changes is inconsistent and not evidence based.<sup>6</sup>

It is recommended that tracheostomies without inner tubes be changed every 7-14 days, with the frequency decreasing as the stoma becomes better formed and pulmonary secretions decrease. EEC guidance, from 1993, states that tracheostomies with inner tubes may be left in place for up to thirty days.

The first change should not occur within 72 hours of the tracheostomy being sited and ideally not for 7 days after a percutaneous insertion. This is to allow for the formation of a more reliable 'track' for the new tube to pass through. Emergency airway equipment, including a smaller tracheostomy tube and emergency drugs, should be immediately available during the change.

The tracheostomy tube may be changed over a soft suction or airway exchange catheter or soft tipped Ryle's tube. The use of a rigid gum-elastic bougie for this purpose may increase the risk of creating a false passage (i.e. the new tracheostomy comes to lie next to, rather than within, the trachea). If a soft tipped Ryle's tube or similar is used, it may be reassuring to see fogging within that tube with respiration. This will help to confirm that the exchange tube is in the airway and not in a false passage prior to passing the new tracheostomy tube. Alternatively, the track may be gently dilated with a gloved little finger.

There should be a low threshold for suspicion of erroneous placement if it is difficult to ventilate the patient. If difficulty is encountered in replacing the tracheostomy tube, the clinical need for a tube must be re-assessed. If in doubt, re-intubation with an oral endotracheal tube may be required.

### Humidification

Cold and unfiltered air is an irritant when inhaled and can lead to increased production and viscosity of secretions. This can be uncomfortable for the patient as well as causing tracheal mucosal keratinisation. The increasingly viscous secretions will be difficult to clear, causing sputum retention, atelectasis, impaired gas exchange and even life threatening blockage of the tracheostomy tube. It is therefore essential that inhaled oxygen is appropriately humidified using conventional techniques such as heat and moisture exchange (HME) filters or heated water baths.

### Nutrition

It is conventional to feed intubated, ventilated patients enterally unless there is a good reason not to. This is usually via a nasogastric or nasojejunal tube, but it may be possible for patients with tracheostomies to be fed orally. However, swallowing is still adversely affected by the presence of a tracheostomy tube, which has a tendency to limit normal movement of the larynx. In addition, the inflated cuff causes a sense of pressure in the upper oesophagus and the difficulty that occurs with swallowing may result in an increased risk of aspiration of food into the lungs.

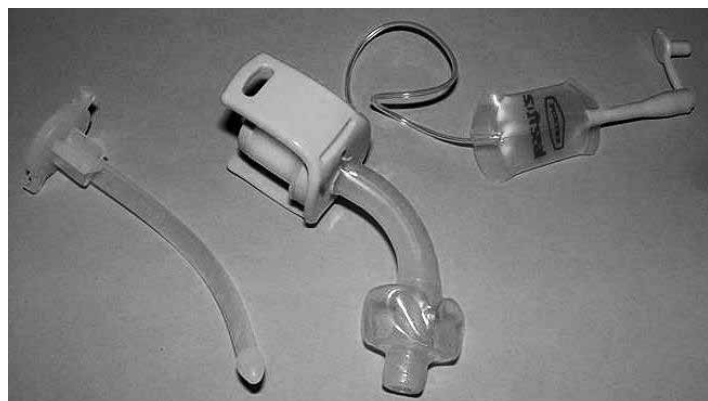Patients may be fed orally, with the cuff inflated or partially deflated, but staff must be alert to signs of aspiration, such as coughing, increased secretions and impaired gas exchange. It is prudent to commence with sips of water and some form of swallowing assessment.

### FEATURES OF TRACHEOSTOMY TUBES

The important features of a tracheostomy tube are as listed below:

#### Diameter

The tracheostomy tube has an inner and an outer diameter. The size of the tracheostomy tube refers to the internal diameter (ID) and ranges from 5.0mm to 9.0mm in adult practice. The size quoted is for the outer tube for single lumen devices, and the inner tube for double lumen devices, but only if the internal cannula is required for connection to a breathing circuit (Figure 2).



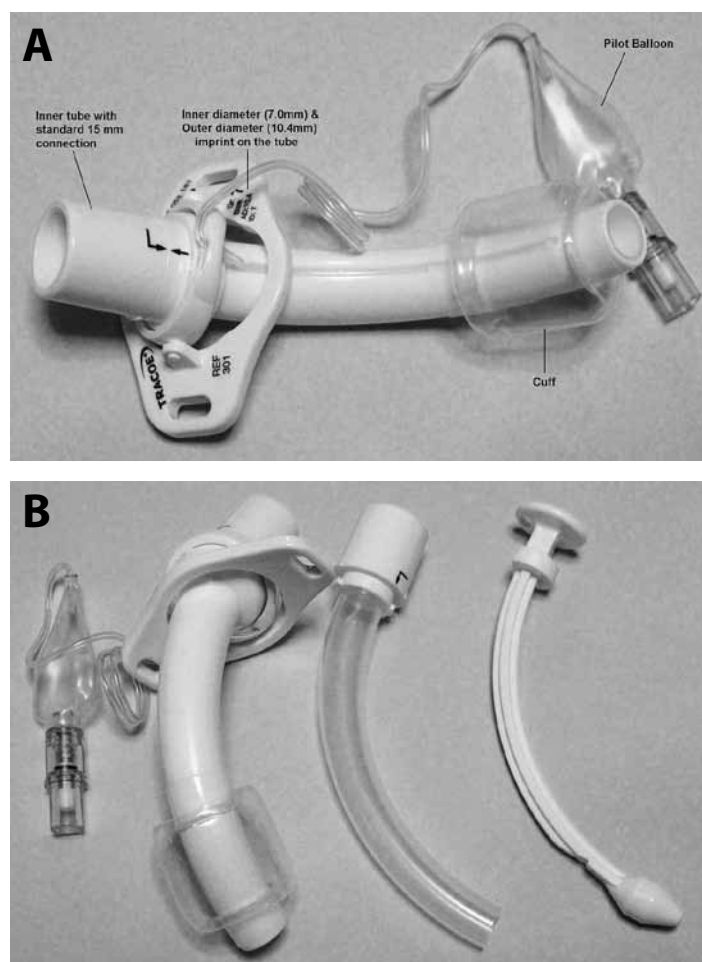
**Figure 2.** A standard, single cannula, size 7.0 tracheostomy tube.

#### Cuff

The cuff reduces aspiration and leakage of air during anaesthesia and positive pressure ventilation. The tube can be changed to an uncuffed tube when mechanical ventilation is not required or when there is deemed to be minimal risk of aspiration. Whilst most patients can be weaned by simply deflating the cuff, it may still restrict airflow around the tube and changing to an uncuffed or smaller tube may help.

#### Inner tube

The inner tube has the advantage of being easily and quickly removed to relieve life threatening obstruction due to blood clots or secretions. This is balanced by the slight reduction in internal diameter, which can result in increased work of breathing and lengthened weaning. It is recommended that dual cannula tubes should be used whenever possible because of this safety advantage (Figure 3).

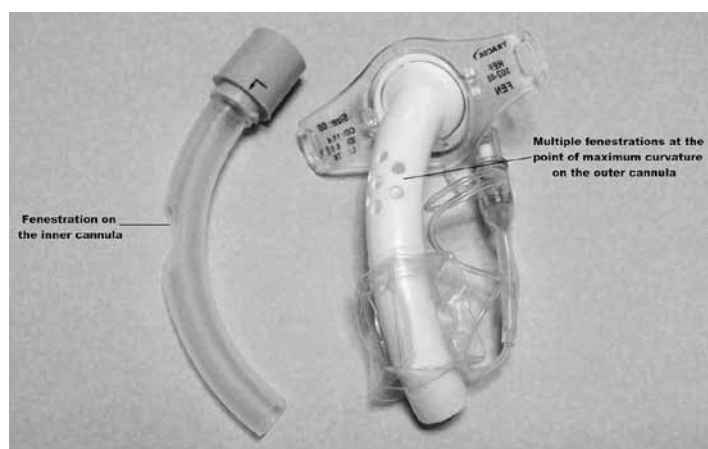


**Figure 3.** Standard, dual cannula tracheostomy tube, A - assembled; B - disassembled, with outer cannula (left), inner cannula (centre) and obturator (right). (Copyright: Dr Rakesh Bhandary).

#### Fenestration

Fenestrations maybe be single or multiple and are positioned at the site of maximum curvature of the tracheostomy tube. These aid speech by allowing airflow through the fenestration into the larynx. The fenestration needs to be well placed for each patient's anatomy, in order to work well. Simply deflating the cuff is an alternative

approach in patients who do not require positive pressure respiratory support (Figure 4).



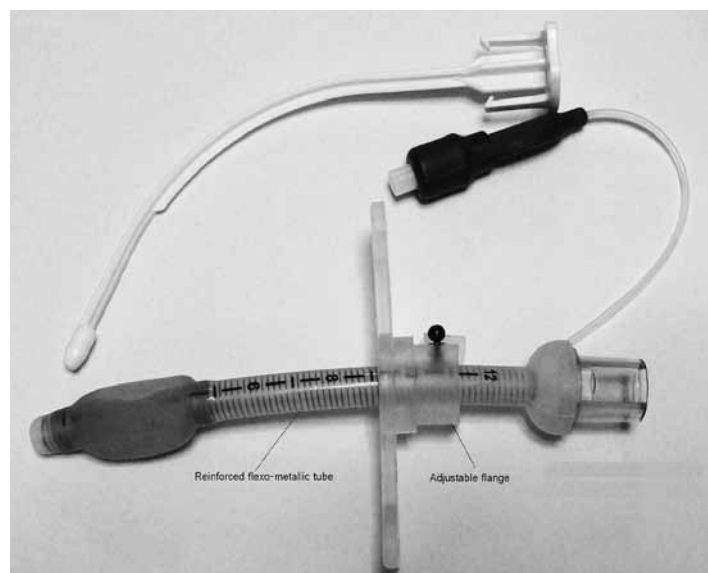
**Figure 4.** A fenestrated dual cannula tracheostomy tube (Copyright: Dr Rakesh Bhandary).

### Flexibility

Flexible or reinforced tracheostomy tubes resemble reinforced endotracheal tubes. They are used in patients where a rigid tube may lie at an angle and cause abrasion or tube obstruction as its lumen abuts the posterior tracheal wall.

### Adjustable flange

The length of the tube from the tracheal lumen to the position of the stoma on the exterior can be adjusted in this variation of the tracheostomy tube. This is useful in obese patients or those with local tissue swelling, where the soft tissue depth is increased (Figure 5).



**Figure 5.** An adjustable flange, flexible tracheostomy tube (Copyright: Dr Rakesh Bhandary).

### Subglottic suction

Some newer tracheostomy tubes include a subglottic suction port, the aim of which is to try and reduce the incidence of ventilator-associated pneumonia.

### Speaking valve

Speaking valves (like the Passy Muir valve) are one-way valves that are designed to be used with fenestrated tracheostomy tubes or unfenestrated tubes (with the cuff deflated). They allow inspiration but not expiration. Hence the expired air is forced through the larynx allowing the patient to phonate (Figure 6).



**Figure 6.** A Passy Muir speaking valve. This is inserted into the external orifice of the tracheostomy tube (Copyright: Dr Rakesh Bhandary).

### COMPLICATIONS OF TRACHEOSTOMY

Complication rates range between 4% and 31% for percutaneous tracheostomy and 6% to 66% for surgical tracheostomy.<sup>7</sup> Kost in 2005 reported on the use of percutaneous tracheostomy in 500 consecutive intubated adults in the intensive care unit.<sup>10</sup> When this procedure was performed in conjunction with bronchoscopy, she stated the complication rate as acceptably low (9.2%). No serious complications (pneumothorax, pneumomediastinum, death) occurred. The 2 most common complications were oxygen desaturation in 14 patients (defined as a drop [even transient] to less than 90%) and bleeding in 12 patients (when intervention was required to control the bleeding).

This is one of many studies that demonstrate a favourable complication rate for the percutaneous method compared to the surgical method.

The complications of tracheostomy can be grouped as immediate, intermediate and long-term and are listed overleaf

### Immediate or early complications

Bleeding is the most common and the most commonly fatal complication of tracheostomy. The incidence is higher in an emergency procedure. Intraoperative bleeding is commonly due to cut edges of the vascular thyroid gland, anterior jugular vessels or inferior thyroid vessels; bleeding in the immediate postoperative period may be exacerbated by emergence from anaesthesia and hypertension. Vasoconstrictors infiltrated during the procedure may also be wearing off.

**Table 1.** The different types of commonly used tracheostomy tubes.

Make	Material	Inner tube	Cuffed / uncuffed	Fenestration	Speaking valve	Flexibility
Portex	Polyurethane	No	Both	No	Yes	Rigid
Shiley	PVC	Yes	Both	Both	Yes	Rigid
Tracoe	Polyurethane	Yes	Both	Both	Yes	Rigid
Bivona	Silicone	No	Cuffed	No	No	Flexible
Negus	Silver	Yes	Uncuffed	Both	Yes	Rigid

Although this may necessitate a return to the operating room, bleeding may be controlled with pressure, local packing – perhaps with dressings or Kaltostat soaked in dilute adrenaline, sutures or hypertension control.

Major bleeding can cause cardiovascular compromise, but may also cause respiratory difficulties, particularly if clots form and obstruct any part of the airway. In this situation, control of the airway should be achieved by conventional intubation, making sure that the cuff of the endotracheal tube is below the stoma. This may require an uncut tube. Surgical exploration is then necessary.

Other early recognised complications include pneumothorax, which may result from direct injury to pleura, pneumomediastinum and injury to local structures like recurrent laryngeal nerve, cartilages and oesophagus.

Malposition of the tracheostomy is always possible but should, in theory, be minimised by the use of fiberoptic bronchoscopy for percutaneous insertions.

### Intermediate complications

Delayed haemorrhage may be due to displaced blood clots or ligatures, infective erosion into a blood vessel or rarely from a tracheoinnominate

fistula, which may result from a long tube or low tracheostomy. As with an endotracheal tube, the tracheostomy tube may also cause tracheal mucosal necrosis at the level of the cuff. The tube may also erode into the surrounding structures leading to tracheoesophageal fistula, pneumothorax or pneumomediastinum. Surgical emphysema may also be seen due to tight closure of tissue around the tube, tight packing material around the tube, or the false passage of the tube into pretracheal tissue.

### Delayed complications

Tracheal stenosis may occur at the level of the stoma due to collapse of the cartilaginous ring or at the level of the tube cuff, due to mucosal necrosis and fibrosis. Modern high volume low-pressure cuffs have reduced the incidence of tracheal stenosis.

A tracheal granuloma may develop or healing may be delayed, leading to a persistent tracheocutaneous fistula or sinus. Sometimes, patients fail occlusion trials or even decannulation for no apparent reason. Possibilities to consider include an obstructing granuloma previously held out of the way with the tube, bilateral vocal cord paralysis, fractured cartilage, and anxiety. Evaluation should include fiberoptic laryngoscopy and bronchoscopy through the stoma.

**Table 2.** Complications of tracheostomy.

Immediate	Intermediate	Long-term
Aspiration	Delayed haemorrhage	Tracheal stenosis
Haemorrhage	Tube displacement	Decannulation problem
Air embolism	Surgical emphysema	Tracheocutaneous fistula
Failure of procedure	Pneumomediastinum	Disfiguring scar
Structural damage to tracheal rings	Pneumothorax	
	Infection	
	Tracheal necrosis	
	Tracheoarterial fistula	
	Tracheoesophageal fistula	
	Dysphagia	

## EMERGENCY MANAGEMENT OF A DISPLACED OR BLOCKED TRACHEOSTOMY TUBE

This complication can be fatal and it is important that those caring for patients with a tracheostomy are alert to its clinical presentation and are familiar with a plan for its management.

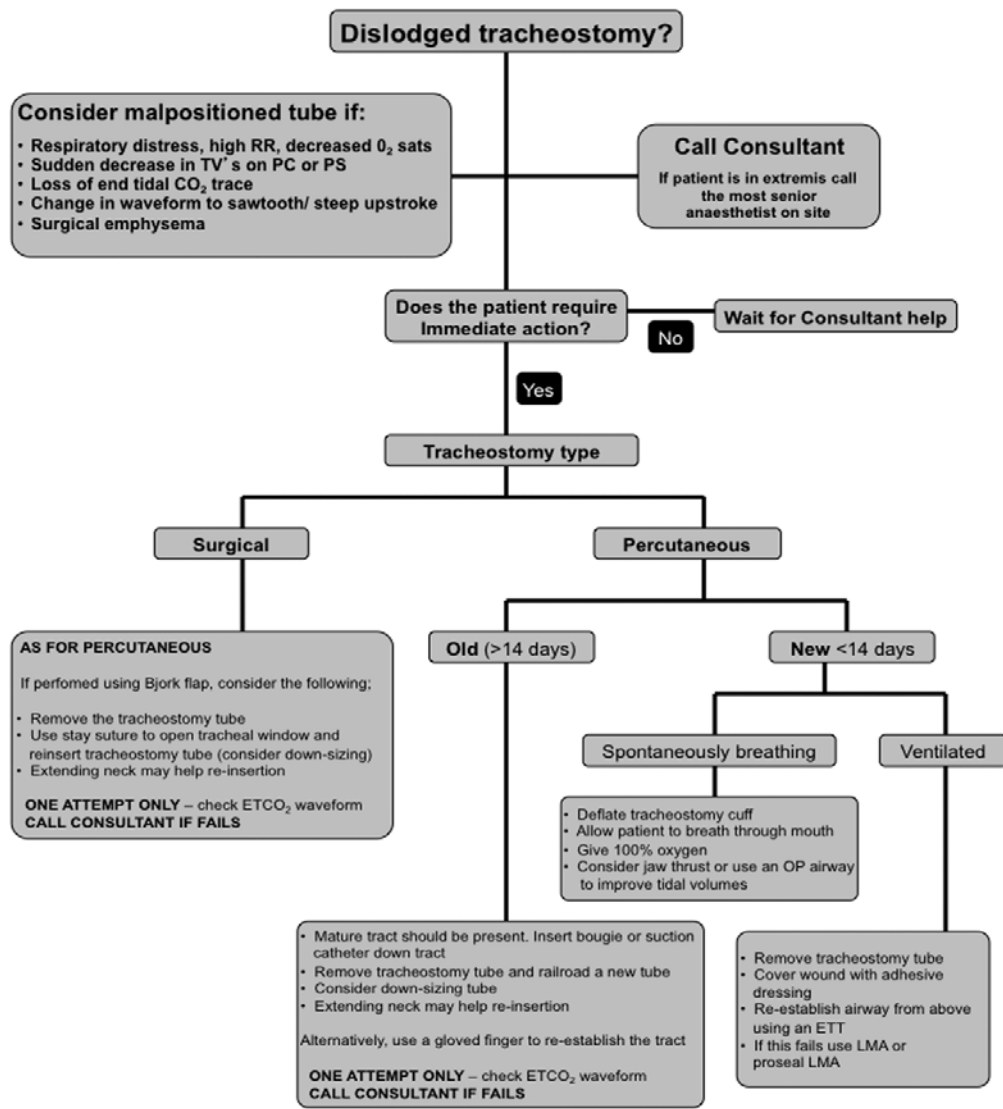
The Royal College of Anaesthetists and Difficult Airway Society recently published the results of the National Audit Project 4 – Major Complications of Airway Management in the United Kingdom.<sup>9</sup> In its Executive Summary, the authors made the following comment on

the management of displaced tracheostomies:

‘Displaced tracheostomy, and to a lesser extent displaced tracheal tubes, were the greatest cause of major morbidity and mortality in ICU. Obese patients were at particular risk of such events and adverse outcome from them. All patients on ICU should have an emergency re-intubation plan.’

An example of an emergency management plan is illustrated in Appendix 2 of the audit’s report whilst another example is provided in Figure 7.

### Critical Care Algorithm for Dislodged Tracheostomy Tube



Re-inserting a tracheostomy tube into a false passage and ventilating through it will lead to surgical emphysema and may make laryngoscopy impossible. **Avoid multiple attempts.** Consider establishing an airway from above **early rather than late.**

The **Bjork flap** is a U-Shaped flap sutured to the lower skin edge producing a well defined tract. Upward and lateral traction on stay sutures placed through the tracheal wall on either side of the tracheostomy will facilitate replacement of the tracheostomy

**Figure 7.** An algorithm for managing a displaced tracheostomy tube. Reproduced with kind permission of Dr Peter Ford, Dept of Anaesthesia, Royal Devon & Exeter NHS Foundation Trust, UK.

Both of these algorithms share some common themes. Understanding that this can become a rapidly fatal complication, emphasis is placed on recognising the clinical picture of a patient with a displaced or blocked tracheostomy tube and calling for senior help early. Advice is given on how and when to attempt to replace the tracheostomy tube but, if in any doubt, the tube should be removed and attempts should be made to maintain and secure the airway from above using a facemask, supraglottic airway devices and ultimately, oral endotracheal intubation.

## WEANING AND DECANNULATION

The tracheostomy tube should be removed as soon as is feasible. Decannulation allows the patient to resume breathing through the upper airway and reduces dependence (psychological and otherwise) on the lower resistance of the tracheostomy tube.

There are many ways of assessing the adequacy of breathing around the tracheostomy tube. Patients can be trialled with increasing periods of cuff deflation. This allows patients to become re-accustomed to swallowing more normally and to having to clear their own secretions.

Alternatively, an occlusion cap may be used which completely blocks the tracheostomy tube. This must be used with a fenestrated tube or an unfenestrated tube with the cuff deflated, and this greatly increases the work of breathing, due to the increased airway resistance. It is harder for patients to breathe in this situation than without the tracheostomy in place and this must be taken into account when interpreting the success or failure of such a trial.

Decannulation can be carried out when:

- The patient is not dependent on ventilatory support and has an adequate respiratory reserve (dead space will be increased without the tracheostomy tube).
- The patient is able to cough and swallow effectively and manage their own secretions, whilst being able to protect their own airway.
- Patient can tolerate cuff deflation or capping of the tracheostomy tube.

Decannulation itself should be performed in the morning, with a rested patient and daylight hours in which to review their progress. The tube is removed and the stoma is covered with a semi-permeable dressing. The patient is encouraged to gently press over this defect with whilst speaking or coughing.

They should subsequently be monitored for signs of respiratory distress. Equipment and expertise to re-secure the airway, either via the stoma or via oral intubation, should be available.

## PERMANENT STOMA, TRACHEOESOPHAGEAL PUNCTURE AND PROSTHETIC SPEECH VALVES

Even though complex laryngectomies are carried out in hospitals providing ENT services, some patients may present themselves to hospitals that do not offer this service. As a result, these patients may present to staff that are less familiar with permanent stomas.

The basic options for speech rehabilitation after total laryngectomy include artificial larynx, oesophageal speech and tracheoesophageal speech. Tracheoesophageal speech provides the advantage over the

other two options, that air supply for speech is pulmonary, phonation sounds natural, and voice restoration occurs within 2 weeks of surgery.

During total laryngectomy, a surgical fistula is created between the oesophagus and the trachea – primary tracheoesophageal puncture (TEP). Alternatively TEP may be performed few weeks or even months after total laryngectomy – secondary TEP. The TEP is kept patent in the immediate postoperative period using a Foley's self retaining catheter or feeding tube, which has the added benefit of enabling enteral feeding. Two to three weeks post-operatively, an appropriately sized Bloom-Singer valve is inserted into the tracheoesophageal fistula.

A Bloom-Singer valve is a hollow, 16- or 20-French, silicone tube that has a one-way flap valve positioned within its proximal tip. The valve serves two purposes; first, it allows the patient to phonate by allowing pulmonary air to pass through the valve, into the pharynx and out of the mouth and second, it prevents saliva and oral secretions from being aspirated into the tracheo-bronchial tree from the pharynx. To phonate, the patient inhales air through the permanent stoma, occludes the permanent stoma with the thumb and then exhales. The occluded stoma diverts air through the Bloom-Singer prosthesis and up the oesophagus to the mouth. Vibration of opposed mucosal surfaces along the oesophagus and pharynx produces a variably husky or hoarse quality voice that is articulated by the tongue, lips, and teeth into intelligible speech.

The following complications may be seen with a Bloom-Singer valve:

- Candida infection in and around the prosthesis
- Leakage through the valve due to a defective one-way valve
- Periprosthetic leakage
- Occlusion of the prosthesis
- Inadvertent displacement and aspiration.

## What to do if a patient presents with displaced Bloom-Singer valve

Two main problems are encountered if a patient presents with a displaced Bloom-Singer valve prosthesis. First, oral secretions may be aspirated into the tracheo-bronchial tree and second, the TEP may be seal spontaneously, warranting another surgical procedure. If these patients present to a hospital that does not provide ENT services, a self-retaining Foley's catheter, equivalent in size to the B-S valve, can be introduced through the TEP into the oesophagus under local anaesthetic spray. The balloon is inflated with 3 ml of air, gently retracted and taped to the side of the neck, while awaiting inter-hospital transfer. If the valve has been aspirated, it can be removed using a fibre-optic bronchoscope.

## REFERENCES

1. Terragni P, Antonelli M, Fumagalli R et al. Early versus late tracheotomy for prevention of pneumonia in mechanically ventilated adult ICU patients: a randomized controlled trial. *JAMA* 2010; **303**:1483-9.
2. Scales D, Thiruchelvam D, Kiss A, Redelmeier DA. The effect of tracheostomy timing during critical illness on long-term survival. *Crit Care Med* 2008; **36**: 2547-57.
3. TRACMAN study. <http://www.pslgroup.com/dg/2361ee.htm>

4. Ciaglia P, Firsching R, Syniec C. Elective percutaneous dilatational tracheostomy. A new simple bedside procedure; preliminary report. *Chest* 1985; **87**: 715-9.
5. Byhahn C, Wilke H, Halbig S, Lischke V, Westphal K. Percutaneous tracheostomy: Ciaglia blue rhino versus the basic Ciaglia technique of percutaneous dilatational tracheostomy. *Anesth Analg* 2000; **91**: 882-6.
6. Standards for the Care of Adult Patients with Temporary Tracheostomy. Standards and Guidelines. The Intensive Care Society, July 2008.
7. Trottier SJ, Hazard PB, Sakabu SA, Levine JH, Troop BR, Thompson JA et al. Posterior tracheal wall perforation during percutaneous dilatational tracheostomy. *Chest* 1999; **115**: 1383-9.
8. Kost KM. Endoscopic percutaneous dilatational tracheotomy: a prospective evaluation of 500 consecutive cases. *Laryngoscope* 2005; **115**: 1-30.
9. Cook T, Woodall N, Frerk C. Major Complications of Airway Management in the United Kingdom. National Audit Project 4. The Royal College of Anaesthetists and the Difficult Airway Society. March 2011. Available at: <http://www.rcoa.ac.uk/nap4/>