

# Update in Anaesthesia

## Large airway obstruction in children

Reprinted with revisions from *Update in Anaesthesia*, (2004)18:44-49. Originally Royal College of Anaesthetists Newsletter 1999; Issue 47: 159-162, reused with permission.

N S Morton

Correspondence Email: neilmorton@mac.com

### Summary

There are anatomical, physiological and developmental reasons for children to be particularly susceptible to airway obstruction.

Rapid clinical assessment, minimal disturbance, and rapid intervention are important. Summon senior experienced help if available.

### PART 1: CAUSES AND ASSESSMENT

Opening and maintaining the airway is fundamental to the treatment of all emergency situations in paediatrics, as in adults. All resuscitation algorithms start with ABC (Airway, Breathing, Circulation) and must be qualified in trauma to include cervical spine control. The commonest cause of paediatric airway obstruction is still the child with depressed conscious level who is not positioned properly or whose airway is not opened adequately by Basic Life Support manoeuvres. Airway foreign bodies are also common and may need rapid intervention. The pattern of infective causes of airway obstruction has changed since the introduction of vaccination programmes against *Haemophilus influenzae* type B. There has been a marked reduction in the incidence of epiglottitis, with a relative predominance now of viral croup and bacterial tracheitis, usually caused by *Staphylococcus aureus*.

### Why are children at increased risk from airway obstruction?

There are anatomical, physiological and developmental reasons for children to be particularly susceptible to airway obstruction.

The nares, upper and lower airways are smaller in absolute terms in children. Resistance to air-flow (and thus the work of breathing) increases during quiet, laminar flow breathing in inverse proportion to the fourth power of the radius. A small decrease in radius of the airway increases markedly the resistance to breathing. This is even more noticeable during crying when air-flow is turbulent as resistance is then related to the fifth power of the radius. An example of this amplification effect in the upset child is to compare the increase in airway resistance when the airway narrows from 4mm to 2mm: in the quiet child the airway resistance increases 16-fold but when the child cries the increase is 32-fold.

The infant has a relatively large tongue and the larynx is situated relatively high in the neck, with the epiglottis at the level of C1 at birth, C3 in the infant and C6 from puberty. The laryngeal inlet appears to lie more anteriorly because of its high position. In the infant, the epiglottis is long and omega shaped and angled away from the long axis of the trachea.

The larynx is funnel shaped and is narrowest at the level of the cricoid ring compared with the cylindrical adult conformation, which is narrowest at the level of the vocal cords. The airway is more compressible as cartilage support components are less well developed. Thus, extrinsic pressure from haematomas, neoplasms, vessels or enlarged heart chambers may more readily compress the airway. The collapse of the laryngeal inlet during inspiration is a feature of laryngomalacia and the collapse of the trachea and/or bronchi during expiration occurs in tracheo-bronchomalacia. If the intrathoracic airways are narrowed from whatever cause, the extra work of inspiration and of expiration leads to large swings in intrathoracic pressure and the potential for gas trapping and hyperinflation behind the obstructed airway causing further compression of small airways. During forced expiration efforts, the intrathoracic airways may collapse down exacerbating the gas trapping effect.

Hyperinflation and gas trapping also impair the function of the diaphragm which is unable to contract so efficiently from its optimal length. In infants the diaphragm has a smaller proportion of contractile elements and fewer fatigue resistant muscle fibres. The rib cage is cartilaginous and more compliant, so the diaphragm anchor points are more mobile, leading to wasted inspiratory work and the clinical sign of recession of the chest wall. The chest wall shape in cross-section is circular in the infant compared with the elliptical shape in the older child and the ribs are attached perpendicular to the vertebral column compared with the acute angle of attachment in the older child. This means that the contribution of the "bucket-handle" movement of the rib cage to inspiration is minimal in small infants and also the elastic recoil effect is much less during expiration. The intercostal muscles and accessory muscles of inspiration are also less well developed. Thus, the small infant is very reliant on the diaphragm's contribution to inspiration and thus has few reserves when work of breathing has to increase. This is on top of the already high basal demands placed on the infant respiratory system by the higher rate of metabolism in early life.

The small absolute size of airways in children means that secretions, small airway constriction, oedema or

**Neil S Morton**

Reader in Anaesthesia,  
Royal Hospital for  
Sick Children  
Glasgow  
UK

compression more readily lead to airway closure and either atelectasis or gas trapping. The interalveolar pores and bronchoalveolar channels do not develop until the ages of 1 year and 8 years respectively so collateral ventilation is not an option around an area of obstruction by these mechanisms.

Thus anatomical, physiological and developmental factors conspire to make the child susceptible to airway obstruction and is exacerbated in disease states (Table 1).

### What are the symptoms and signs of airway obstruction?

#### Signs of foreign body aspiration

Sudden onset of respiratory compromise associated with coughing, gagging, choking, aphonia or stridor suggests foreign body aspiration and this may necessitate emergency basic life support measures for the choking child. Signs of gas trapping behind a foreign body (“ball-valve effect”) may be seen with hyper-resonance of the hemithorax, loss of percussion dullness over the liver, surgical emphysema, tracheal deviation and unequal breath sounds. It is particularly important to think of the possibility of pneumothorax and actively exclude it and treat it promptly. Pneumomediastinum, pneumopericardium and pneumoperitoneum may be seen. Collapse or consolidation of lobes or lungs with bronchial breathing, widespread crackles and expiratory wheeze may all be elicited depending on the cause, site and duration of the airway obstruction.

#### Signs of increased work of breathing

The increased effort of breathing caused by airway obstruction may produce an increase in respiratory rate for age. A rate >50bpm in an infant and >30bpm in a child may be considered abnormal. However, of even more concern would be respiratory distress associated with a normal respiratory rate, bradypnoea or apnoeic spells which indicate decompensation and exhaustion.

A “see-saw” pattern of chest and abdominal breathing movements is seen in airway obstruction. This sign occurs earlier in younger infants. Recession of the intercostal spaces, subcostal region and sternum are also seen early in young infants and reflect the forces generated by vigorous contractions of the diaphragm and the compliant chest wall. If recessions are seen in older children they indicate severe airway obstruction. Use of the accessory muscles of inspiration (sternomastoids, scalene muscles and intercostals) is associated with tracheal tug, suprasternal and supraclavicular recessions and nasal flaring. Often the child sits upright and may adopt the “tripod” position to improve the mechanical advantage of these muscles in moving the chest wall and that of the diaphragm. In the small infant, an opisthotonic posture may be seen in airway obstruction and head bobbing is a sign of accessory muscle contraction in the infant. Lack of effort associated with deteriorating conscious level may indicate exhaustion and decompensation.

Expiratory grunting is often noted in infants with respiratory distress who are trying to generate auto-CPAP or expiratory braking at laryngeal level to maintain a residual lung volume at end expiration.

Stridor during inspiration is usually a sign of airway obstruction at supraglottic or laryngeal level but can occur in tracheal obstruction also. Stridor during expiration is usually a sign of intrathoracic airway obstruction. Prolonged expiration with wheeze is usually a sign of small airways obstruction as in bronchiolitis or asthma but can occur in large airway obstruction especially due to foreign body or if there is an underlying anatomical abnormality. The volume of stridor or wheeze does not correlate with the degree of airway obstruction. Indeed, the most ominous sign is the “silent chest” where obstruction is so severe that no gas flow is occurring.

#### Signs of ineffective breathing

Cyanosis, depression of conscious level, slow respiratory rate, the

**Table 1.** Some causes of large airway obstruction in children

---

Depressed conscious level

Foreign body

Infection

- Viral: croup, papillomatosis
- Bacterial: epiglottitis, tracheitis, tonsillitis, abscess
- Adjacent to airway

Trauma

Thermal injury

Congenital abnormalities: choanal atresia, choanal stenosis, micrognathia, macroglossia, laryngomalacia, laryngeal web

Neoplasm: haemangioma, lymphoma, mediastinal mass

Peripheral neurological disease

Neuromuscular disease

Iatrogenic: subglottic stenosis, post-intubation stridor, neck haematoma

Anaphylactoid reactions

---

silent chest despite vigorous respiratory efforts or lack of adequate respiratory effort, apnoeic spells and bradycardia are most worrying signs of ineffective breathing.

### Secondary effects of airway obstruction

Airway obstruction may produce hypoxaemia and hypercarbia. Tachycardia, sweating, confusion, restlessness, agitation, anxiety, dyspnoea, inability to speak, peripheral vasoconstriction with pallor or mottling, cyanosis, decreased conscious level, apnoeic spells and bradycardia may occur. Generalised convulsions may occur secondary to hypoxaemia. Hypertension and bounding pulses may be felt and pulsus paradoxus of greater than 20 mmHg may be elicited in older children. Chronic airway obstruction may cause chest wall abnormalities, pulmonary hypertension, right heart failure and obstructive sleep apnoea syndrome.

### What investigations are helpful?

The assessment of the child in order to identify and manage airway obstruction is a clinical one. Do not try to examine the child's throat. The pulse oximeter is a very helpful, non-invasive and atraumatic monitor of arterial oxyhaemoglobin saturation and heart rate. However, the readings need interpretation in context with the clinical picture as they are affected by poor perfusion, movement, ambient light and carboxyhaemoglobinaemia (as may occur in smoke inhalation injury) and are less accurate at values below 70%.

Radiology should not be used in the child in extremis before intervening but in the less acute situation may help elucidate chest signs, such as pneumothorax, consolidation, collapse, foreign body, steeple sign in croup, mediastinal mass, etc. It should be carried out at the bedside.

Lateral soft tissue neck films are seldom indicated but may show a foreign body, thumb sign of epiglottitis, prevertebral or a retropharyngeal abscess. CT and MRI scanning have no place in emergency management but are very helpful in cases such as haemangioma, mediastinal mass, or abscess adjacent to the airway.

The process of obtaining arterial, capillary or venous blood gases is likely to cause undue distress which will worsen airway obstruction. In the obtunded child intervention should be immediate and should not await blood gas results. For less severe cases, trends in carbon dioxide levels, pH and oxygen values may be helpful in guiding treatment and in reinforcing the need to intervene. Chronic airway obstruction leads to a respiratory acidosis which induces renal compensatory mechanisms with retention of bicarbonate and a metabolic alkalosis reflected in a high serum bicarbonate level and often a near normal arterial pH.

### Making the diagnosis

Some features of the history and examination may be particularly helpful in pointing to a specific diagnosis and they are summarised in Table 2. These clinical signs are suggestive only as each disease process has a spectrum of severity. In individual cases it can be difficult to differentiate between the infective causes and foreign body aspiration. Severe tonsillitis or abscesses near the airway can produce similar symptoms and signs. Oedema of the face, periorbital tissues, tongue and peripheries is suggestive of angioneurotic oedema or anaphylactoid reactions.

### Severity scoring system

A scoring system for croup (Table 3) is helpful in assessing severity, response to therapy and of the need for intervention

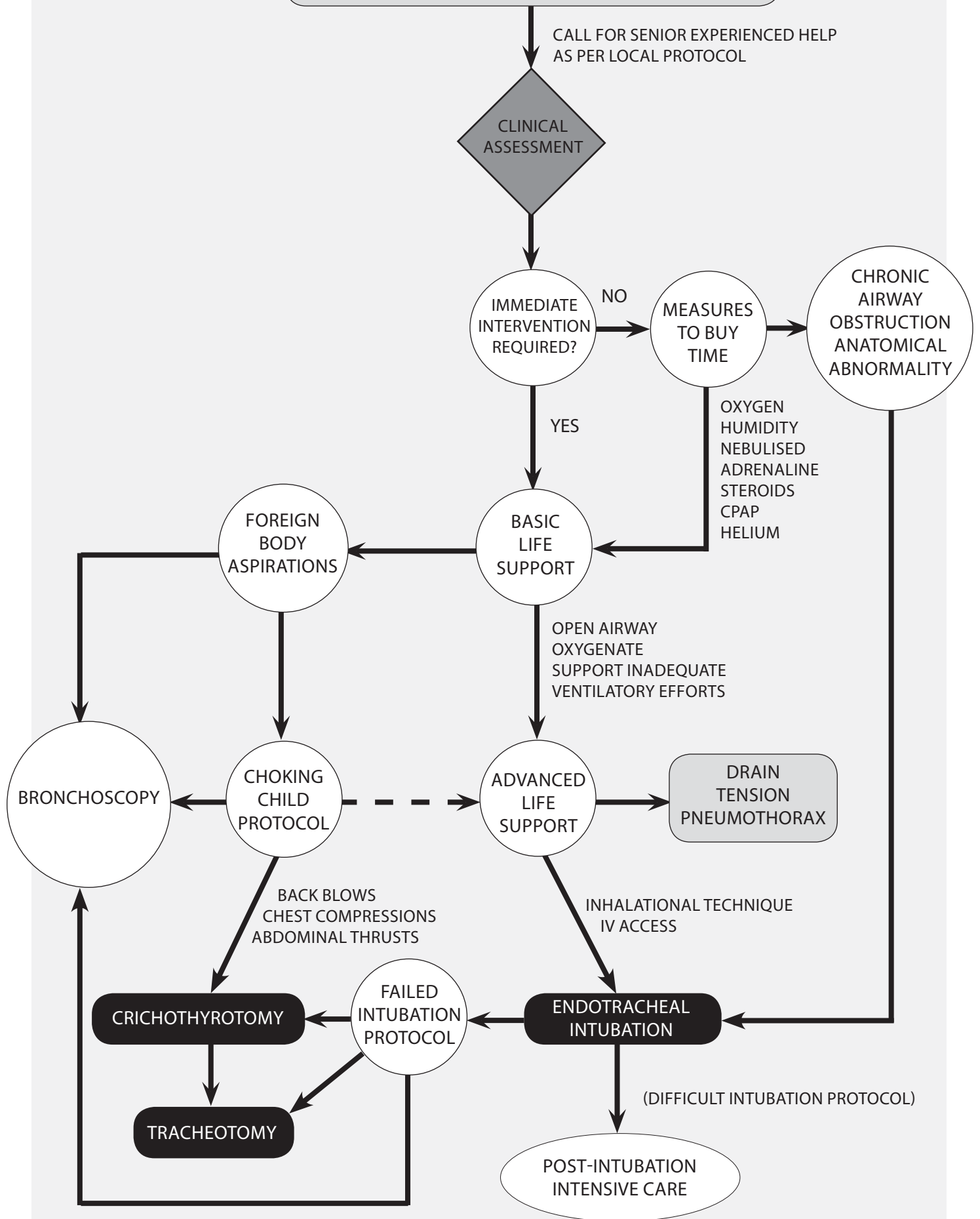
**Table 2.** Differentiation between croup, tracheitis and epiglottitis

	<b>Croup</b>	<b>Tracheitis</b>	<b>Epiglottitis</b>
<b>Cause</b>	Viral	Staphylococcus aureus Streptococcus	Haemophilus influenzae B
<b>Age</b>	6m – 3y	Any age	2 – 6y
<b>Onset</b>	Gradual	Gradual	Sudden
<b>Pyrexia</b>	Mild	>38°C	>38°C
<b>Abnormal sounds</b>	Barky cough, stridor	Barky cough, stridor	Muffled, guttural cough
<b>Swallowing</b>	Normal	Difficult	Very difficult with drooling
<b>Posture</b>	Recumbent	Sitting	Tripod position
<b>Facies</b>	Normal	Anxious	Anxious, distressed, toxemic

**Table 3.** Croup score

	<b>0</b>	<b>1</b>	<b>2</b>
<b>Breath sounds</b>	Normal	Harsh, rhonchi	Delayed
<b>Stridor</b>	None	Inspiratory	Insp. + Exp.
<b>Cough</b>	None	Hoarse cry	Bark
<b>Retractions/ flaring</b>	None	Flaring + suprasternal retractions	Flaring + suprasternal + intercostal retractions
<b>Cyanosis</b>	None	In air	In 40% oxygen

# Paediatric Large Airways Obstruction



## PART 2: MANAGEMENT

### Importance of rapid clinical assessment, minimal disturbance and rapid intervention

An assessment from the end of the bed with minimal disturbance should be possible in most cases with the child sitting in the parent's arms and the child should be allowed to adopt the posture in which they are most comfortable. Clinical assessment and a concise history as described in part 1 should allow identification of the need for intervention. A pulse oximeter probe is relatively atraumatic to apply. Gentle physical examination of the chest seeking actively for the important signs described in part 1 should be possible. In some cases, the need for immediate intervention will be obvious. In others, measures to buy time to enable experienced help to arrive may be appropriate. It is often stated that attempts at venous access should not be made as they will upset the child - this is a reasonable view. However, some argue that, in the less ill child and with topical local anaesthesia or ice analgesia of the skin and a skilled paediatric venepuncturist, this is not an issue. Some experienced paediatric anaesthetists are of the view that, in the hypercarbic, obtunded child with a hyperdynamic circulation, establishing venous access is relatively simple and appropriate. Despite this debate, the classical approach of not attempting venepuncture is recommended for the non-specialist anaesthetist.

### When is immediate intervention required to open the airway?

Immediate intervention is needed in the choking child or if the child is apnoeic or exhausted and making ineffective respiratory efforts. A silent chest or no stridor (either in the child making maximum effort to breathe or in the exhausted child) are very sinister indications of complete airway obstruction. The simultaneous treatment priorities are oxygenation, opening the airway, improving failing respiratory efforts and relieving tension pneumothorax.

#### *Can I "buy time" prior to intervening to secure the airway?*

Steroids improve airway patency in croup, haemangioma, lymphoma and some mediastinal masses. They can be given orally, parenterally or by nebuliser. Prednisolone 4mg.kg<sup>-1</sup> orally, or dexamethasone 0.6mg.kg<sup>-1</sup> intravenously or intramuscularly, or budesonide 1-2mg by nebuliser are favoured as initial therapy with maintenance by repeated nebuliser therapy or oral prednisolone or parenteral dexamethasone at one quarter of the initial dose every 8-12h for up to 48h. Prompt administration of steroids often pre-empts the need for intubation in most cases of moderate or severe croup.

Nebulised adrenaline 1:1000 standard solution at a dose of 0.5ml.kg<sup>-1</sup> (maximum 5ml) diluted if necessary with 0.9% saline to a total volume of 5ml will give a dose of 2-5mg in most cases. It reduces mucosal oedema and acts very rapidly but when stopped may give rise to a rebound worsening of airway obstruction. It is a useful temporising measure. ECG monitoring is recommended although dysrhythmias are seldom a problem.

CPAP - Continuous positive airway pressure acts as an effective splint for the collapsible, compressible paediatric upper airway and can be delivered to infants and children by a well fitting facemask (especially using the Jackson-Rees T-piece circuit) and, in babies, by nasal

cannulae, nasal prongs or a nasopharyngeal airway. It is a very useful measure particularly during the preparation phase prior to intubation and during inhalational induction of anaesthesia. It can be very useful in the management of chronic airway obstruction. A development of CPAP is bi-level CPAP or BIPAP; it is becoming increasingly popular in the management of children.

Prone position +/- nasopharyngeal airway can be useful in babies with congenital upper airway abnormalities where the tongue is relatively large eg hemifacial microsomia, Pierre-Robin syndrome, or Treacher-Collins syndrome. The tongue falls forward from the posterior pharyngeal wall and often improves the airway. In conjunction with nasal CPAP and /or a nasopharyngeal airway, the child may improve markedly with this simple manoeuvre.

Helium is less dense than air or oxygen and gas flow tends to be more laminar which reduces the work of breathing. However, it is not readily available, is expensive and dilutes the inspired oxygen concentration. Breathing a helium-oxygen mixture may be helpful in buying time.

#### *How should I intervene to open and secure the airway?*

The algorithm in Figure 1 is a useful guide. If possible, call for expert help.

### Basic life support manoeuvres and the choking child

Head tilt, chin lift and jaw thrust are the first basic steps. Physical methods of clearing the airway should only be used if the diagnosis of foreign body aspiration is clear and dyspnoea is increasing rapidly or apnoea has occurred. Do not use finger sweeps as this may push the foreign body further down the airway and may impact it in the laryngeal inlet. Do not try to examine the throat. In infants, immediately carry out five back blows with the heel of the hand with the infant lying prone and head down along your arm which should be resting along your thigh. If the obstruction remains, turn the baby supine and give five chest thrusts as for cardiac compression but more slowly and repeat airway opening manoeuvres, expired air ventilation and cardiac compressions as appropriate. In older infants and children, five back blows with the child prone across the lap and up to five abdominal thrusts exactly in the midline with the child standing, kneeling, sitting or supine should be used.

### Advanced life support manoeuvres

Oxygen 100% should be administered by self-inflating bag and mask or anaesthetic T-piece circuit, depending on familiarity. The latter has the advantage that CPAP can easily be applied and the transition from spontaneous to controlled ventilation is simple. It is very important to actively exclude tension pneumothorax and, if present, to intervene with a needle, cannula or drain. This can be inserted under local anaesthesia in the conscious child giving careful attention to technique. Some distress may be caused to the child but this is transient and justifiable in the emergency situation. In the context of a tension pneumothorax secondary to acute airway obstruction, it is very wise to drain the pneumothorax prior to inducing anaesthesia. However, circumstances may dictate simultaneous intervention to drain the pneumothorax and induce anaesthesia to secure the airway if rapid decompensation is occurring.

### Endotracheal intubation technique

It is better to have the child in an intensive care or operating theatre



environment. Senior experienced staff only should attempt intubation unless circumstances mandate a life-saving attempt. Some recommend calling for assistance from the ENT team in case a bronchoscopy or tracheostomy is needed. A wide range of paediatric airway and intubation equipment should be to hand and checked.

Inhalational induction of anaesthesia with halothane (increasing gradually to 5%) in oxygen, starting with the child in the position in which they are most comfortable is recommended. Some experts now prefer sevoflurane (starting with 8%) in oxygen but experience in children with critical airway obstruction is limited and sevoflurane is intrinsically less potent making it difficult to gain a sufficient depth of anaesthesia to allow intubation. Remember, alveolar ventilation may be severely compromised and uptake of volatile agents may be very slow. It may take up to 10 minutes to reach a sufficient depth of anaesthesia. As the depth of anaesthesia increases and the patient is moved to the supine position, airway obstruction may occur and it is wise to change position gradually and to add CPAP to splint the airway open. Once the pupils become constricted and central, wait for a further 30 breaths and then perform laryngoscopy and orotracheal intubation. Change to a nasotracheal tube once the child is stabilised and fix securely with tape or a tube holder and fixation system (eg Tunstall, Burtles, Secure-ET).

If intubation is difficult or impossible, a number of techniques using the flexible fiberoptic or rigid bronchoscope are possible and very occasionally blind or retrograde intubation techniques may be employed. The use of a nasopharyngeal airway or the laryngeal mask airway may be helpful in certain cases. All these techniques are for the expert only.

In certain cases of impossible intubation where the child is rapidly deteriorating, the safest option may be to consider an emergency cricothyrotomy using a cannula, 3mm endotracheal tube connector, a T-piece or self inflating bag and oxygen source. Remember that there must also be a patent expiratory pathway to avoid barotrauma. Carbon dioxide levels will tend to rise with this technique. Jet ventilation is not recommended in children due to the risks of overpressure and barotrauma. In other cases, particularly of severe anatomical abnormalities, the safest option may be an emergency tracheostomy under mask anaesthesia and or local infiltration analgesia.

#### *When should I not intervene?*

If you are inexperienced with advanced life support measures in children, you should try to maintain oxygenation, airway patency and ventilatory support with basic measures until experienced staff arrive. Advanced life support interventions should be carried out by the most experienced staff present. However, you may have to intervene in the extreme situation to save the child's life. If it is available, it is vital that expert help is called as early as possible to manage children with airway obstruction.

#### *How should I manage the child after the airway is secured?*

It is important to ensure that the artificial airway is fixed securely and is correctly positioned. A post-intubation chest X-ray is useful for checking tube position and identifying lower respiratory tract or pulmonary parenchymal changes. Indications for controlling ventilation rather than allowing spontaneous ventilation are:

- Small diameter endotracheal tube
- Child with signs of septicaemia
- Lower respiratory or lung disease
- Child who has sustained a hypoxic insult
- Very abnormal, inflamed or oedematous airway
- Traumatic intubation
- Need to transport the child to another hospital

Sedation, analgesia and muscle relaxation should be given as appropriate. Some children develop post-intubation pulmonary oedema which requires ventilatory support with PEEP and diuretic therapy.

Antibiotic therapy is indicated for likely organisms - the third or fourth generation cephalosporins are favoured with some preferring flucloxacillin for staphylococcal tracheitis. Duration of intubation varies widely from 18-24 hours for acute epiglottitis to days or weeks for those with lung involvement, severe disease and pre-existing congenital anomalies. Some children may require formal investigation of their airway eg endoscopy, foreign body removal or reconstructive surgery.

### **CONCLUSION**

Large airway obstruction in children is a common emergency. If available, senior experienced help should be summoned immediately. Therapy is guided by clinical assessments. All consultants should be competent in the performance of basic life support measures for the choking child and for opening the airway, oxygenating the child and supporting inadequate ventilation. Measures to buy time can be very helpful in croup and where the airway anatomy is abnormal. Advanced life support measures are for experienced staff but you may have to intervene immediately to save a child's life. The results of correct management are excellent.

### **FURTHER READING**

- Morton NS. Large airway obstruction in children. *Update in Anaesthesia* (2004) **18**:44-49. Available from: [http://www.wfsahq.org/components/com\\_virtual\\_library/media/92df8f6507212855c41926db87562732-9872ec3f9b81c17cad5c78fcbaa5d71c-Large-Airway-Obstruction-in-Children-Update-18-2004-.pdf](http://www.wfsahq.org/components/com_virtual_library/media/92df8f6507212855c41926db87562732-9872ec3f9b81c17cad5c78fcbaa5d71c-Large-Airway-Obstruction-in-Children-Update-18-2004-.pdf)
1. Kissoon N. Acute respiratory emergencies. In: Duncan A, ed. *Paediatric Intensive Care*. London: BMJ Books, 1998:9-40.
  2. Robinson D. Airway management. In: Morton N, ed. *Paediatric Intensive Care*. Oxford: Oxford University Press, 1997:81-108.
  3. Advanced Life Support Group. *Basic Life Support. Advanced Paediatric Life Support*. 5th ed. London: BMJ Publishing Group [Wiley-Blackwell], 2005:19-33.
  4. Morton NS, Doyle EI. Case Presentations in Paediatric Anaesthesia and Intensive Care. Oxford: Butterworth-Heinemann, 1994.
  5. Morton NS. Large airway obstruction in children. Part 1: Causes and Assessment. *Royal College of Anaesthetists Newsletter* 1999; Issue 47: 159-162.
  6. Kissoon N. Acute respiratory emergencies. In: Duncan A, ed. *Paediatric Intensive Care*. London: BMJ Books, 1998:9-40.
  7. Robinson D. Airway management. In: Morton N, ed. *Paediatric Intensive Care*. Oxford: Oxford University Press, 1997:81-108.
  8. Morton NS, Doyle EI. Case Presentations in Paediatric Anaesthesia and Intensive Care. Oxford: Butterworth-Heinemann, 1994.
  9. Special Issue: The Pediatric Airway. *Pediatric Anesthesia*, July 2009;19s1:III-IV, 1-197. Available at: <http://onlinelibrary.wiley.com/doi/10.1111/pan.2009.19.issue-s1/issuetoc>