

Typhoid enteric – part 2: anaesthesia in a child with typhoid intestinal perforation

Falan Mouton, Esohe Oluoba and Ibironke Desalu

Correspondence: bruce.mccormick@nhs.net

Originally published as *Anaesthesia Tutorial of the Week*, 339, 14 October 2016, edited by Catharine Wilson and Faye Evans

Summary

Typhoid intestinal perforation is a surgical emergency that is potentially fatal.

Children account for more than half of cases.

The role of the anaesthetist in the management includes aggressive fluid resuscitation, correction of electrolyte imbalance, use of intravenous broad-spectrum antibiotics, formulation of an appropriate anaesthetic plan and postoperative management in a HDU/ICU.

Vigilance by the anaesthesia provider is critical to the patient's survival.

perforation is the terminal ileum, though it can occur anywhere in the intestine.^{1,3}

MANAGEMENT OF TYPHOID INTESTINAL PERFORATION

History and presentation

Many patients seek professional medical attention late, after weeks of symptoms, and following attempts at treatment with antibiotics or traditional medications. Though symptoms may be atypical in infants and toddlers less than 5 years old, the classical form displays some typical presenting features (Table 1).¹

INTRODUCTION

Typhoid fever is a common infection in developing countries and where unhealthy environmental conditions prevail. The annual global incidence of typhoid fever according to the World Health Organization is 21 million cases, with 1–4% mortality.¹ In sub-Saharan Africa, it predominantly affects children below the age of 15 years with a mortality of 24%.²

Typhoid intestinal perforation, which is the most serious complication of typhoid fever, has a global incidence rate of 0.6–4.9%; however, in West Africa, higher rates, of 10–33%, have been reported.³ Children account for more than 50% of these cases of typhoid intestinal perforation, with boys and girls equally affected. Typhoid infection is caused by the bacteria *Salmonella typhi* (also known as *Salmonella enterica* serotype *typhi*), a Gram-negative flagellated rod found only in humans, and also by *Salmonella paratyphi*. The bacteria are transmitted by ingestion of food or water contaminated with faeces. The organism has no exotoxin; however, it is strongly antigenic causing an intense inflammatory reaction in tissues where it is present. The commonest site of intestinal

Assessment

On general examination, a child with typhoid intestinal perforation will be ill-looking and toxic. There may be pyrexia, pallor and jaundice. If the illness has lasted several weeks, the child may appear wasted and demonstrate an altered level of consciousness.

Physical examination of the abdomen frequently reveals distension with associated guarding and rigidity. Plain abdominal radiograph (erect film) will show air under the diaphragm. Children too sick to stand erect may have a lateral decubitus film which will show pneumoperitoneum (Figure 1). Abdominal ultrasound can be used to exclude other intra-abdominal conditions that can complicate typhoid fever such as cholecystitis or intraperitoneal abscesses.¹

Preoperative optimisation

High-flow oxygen should be commenced via a facemask with a reservoir bag. If the child is obtunded, the airway should be secured with an endotracheal tube. Abdominal distension can result in splinting of the diaphragm, leading to respiratory compromise.

Falan Mouton

Paediatric Anaesthesia
Fellow
Lagos University Teaching
Hospital
Lagos
Nigeria

Dr Esohe I Oluoba

Consultant anaesthetist
Lagos University Teaching
Hospital
Lagos
Nigeria

Ibironke Desalu

Professor of Anaesthesia
University of Lagos
Lagos
Nigeria

Table 1. Presenting features of typhoid intestinal perforation

Fever	Earliest symptom and commonly precedes abdominal pain (differentiates it from appendicitis, in which abdominal pain precedes fever), often associated with throbbing frontal headache.
Abdominal pain	Usually begins 2–30 days (average of 9 days) after onset of fever. It is initially vague but gradually becomes generalised. With perforation, abdomen distension is commonly noted.
Diarrhoea	Common in the early stages of but constipation is predominant later in the course of the illness.
Gastrointestinal bleeding	A history of passage of frank or altered blood in stools may also be present.

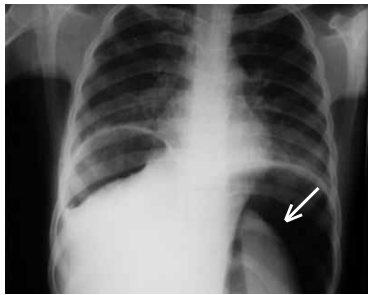


Figure 1. Plain chest radiograph showing massive pneumoperitoneum (arrow) (photograph supplied by Professor Emmanuel Ameh, Paediatric surgeon, National Hospital, Abuja, Nigeria)

In some cases, pneumonia may develop. An appropriately sized nasogastric tube (NGT) should be inserted and the stomach decompressed by low-pressure suction or intermittent aspiration.

The haemodynamic condition of the patient must be evaluated. Tachycardia, hypotension, a capillary refill time (CRT) of longer than 3 seconds, and oliguria are all suggestive of dehydration and shock and will require immediate intervention. Intravenous access via two wide-bore cannulae should be secured and samples drawn for relevant investigations. When adequate peripheral access cannot be obtained, a central venous or intraosseous line should be obtained. Fluid resuscitation with a bolus of 20 mL kg⁻¹ isotonic crystalloids such as 0.9% saline should be commenced as soon as possible, after which the patient should be reassessed. Fluid boluses may need to be repeated depending on how the patient responds to the initial bolus. Inotropes, vasopressors or a combination of both should be added if shock is not responding to fluid resuscitation (see ‘Management of paediatric sepsis’, page 33 in this edition of *Update in Anaesthesia*).

A full blood count may reveal anaemia with leucocytosis or even leucopenia. Serum biochemistry may show clinically significant alterations in potassium and sodium concentrations with a metabolic

acidosis. Urea and creatinine may be elevated, heralding renal compromise. Clotting profile is indicated if there is evidence of coagulopathy. The Widal test (an agglutination test that detects the presence of serum agglutinins H and O in the serum of patients with typhoid and paratyphoid fever) has been found to be non-specific with limited usefulness in management of these patients.¹ Regardless of laboratory findings, the diagnosis of typhoid intestinal perforation requires a high index of suspicion as tests may not be readily available in areas where typhoid is endemic.

Intravenous broad-spectrum antibiotics (directed against Gram-negative and anaerobic bacteria) should be commenced immediately once the diagnosis of typhoid perforation is suspected. The antibiotics may be changed later if there is no improvement and when culture results are available.

In areas such as sub-Saharan Africa where there is a high prevalence of multidrug-resistant (MDR) strains, the following combinations are currently recommended:^{1,4}

A quinolone, e.g. ciprofloxacin 10 mg kg⁻¹ (max. 400 mg 8-hourly) + metronidazole 7.5 mg kg⁻¹ (max. 500 mg 8-hourly)
or
A third-generation cephalosporin, e.g. ceftriaxone 50–75 mg kg⁻¹ (max. 4 g day⁻¹) + metronidazole 7.5 mg kg⁻¹ (max. 500 mg 8-hourly)

In areas where the prevalent strain of bacterium is still susceptible, the following regimen can be used:

Chloramphenicol 100 mg kg⁻¹ day⁻¹ in divided doses IV + metronidazole
or
Amoxicillin 100 mg kg⁻¹ day⁻¹ in divided doses IV + metronidazole
or
Trimethoprim–sulphamethoxazole 20 mg kg⁻¹ day⁻¹ in divided doses IV + metronidazole

Blood should be typed and cross-matched for correction of anaemia and for intraoperative use.

The definitive treatment for typhoid intestinal perforation is operative evacuation of faecal matter to avoid further contamination. Surgical options include resection of the affected intestine, simple closure of perforations and enterostomy, which is performed if the child is too sick or the intestinal oedema too extensive for safe anastomosis or simple closure.^{1,5}

Measures to optimise the patient's preoperative status are summarised in Table 2.

ANAESTHETIC MANAGEMENT

Preoperative preparation

Children presenting to the theatre for repair of typhoid perforation are usually quite ill: American Society of Anesthesiologists (ASA) classification 3 or 4E. The anaesthetist must be prepared for a potentially unstable and challenging paediatric patient. Adequate IV access must be ensured with two large-bore cannulae. The patient may be volume depleted or vasoconstricted, making peripheral access challenging; in such cases, a central venous line is an acceptable alternative. An intraosseus line should be considered if attempts at insertion of a peripheral or central line fail. The patient should be adequately resuscitated before induction is attempted.

Standard anaesthesia monitoring should be instituted prior to induction. Plethysmography and measurement of oxygen saturation and blood pressure are particularly useful in monitoring oxygenation and circulation. Capnography is useful in determining correct placement of an endotracheal tube, monitoring and modifying ventilation as well as monitoring adequacy of circulation. Clinical parameters such as capillary refill time, warmth at peripheries and urinary output of at least $0.5 \text{ mL kg}^{-1} \text{ h}^{-1}$ are as important as equipment monitoring. If

available, an arterial line is useful in detecting sudden haemodynamic shifts, obtaining frequent blood samples and guiding resuscitation efforts.

Temperature homeostasis is of particular concern because of pre-existing fluid losses, large area of potential intraoperative evaporative loss and large volumes of resuscitation fluid that may need to be administered. Temperature can be maintained by keeping the theatre warm, warming intravenous and irrigating solutions, covering the exposed gut with warm saline packs, covering the head and extremities with warm towels and using a heat and moisture exchange filter on the breathing circuit. A warming mattress or convection warming is ideal.

Induction

Patients with typhoid intestinal perforation may have significant hypotension at induction of anaesthesia as a result of the active systemic inflammatory response and resultant vasodilation. Volume resuscitation should be started prior to induction and continued throughout the operative period. Despite preoperative fluid boluses and inotropes/vasopressors, the anaesthesia provider should be prepared for cardiovascular collapse at induction or during the procedure.

The anaesthetic technique of choice is general anaesthesia with endotracheal intubation and ventilation. Patients with typhoid fever should be regarded as having a full stomach. After pre-oxygenation, a rapid sequence induction with cricoid pressure should be used to secure the airway as patients are at risk of regurgitation and aspiration. A competent assistant should be available to provide cricoid pressure ensuring that it does not compromise laryngeal view and therefore intubation. Prior to induction, the nasogastric tube must be suctioned. Despite adequate pre-oxygenation, the child will still be prone to a period of severe desaturation at intubation as the distended abdomen decreases the functional residual capacity (FRC). To improve FRC, patients may be intubated in the reverse Trendelenburg position.

Anaesthetic drugs for induction and maintenance should be carefully selected to help maintain haemodynamic stability and minimise additional peripheral vasodilation. Drugs that increase vasodilatation, such as propofol, should be avoided if possible. Drugs that maintain sympathetic tone should be selected as they will help to support haemodynamic stability. In many settings, ketamine is the drug of choice as it supports circulation, especially if hypovolaemia is still suspected. It should be used at a dose of $1\text{--}2 \text{ mg kg}^{-1}$ IV. Thiopentone may also be used, but with caution, especially where fluid resuscitation has not been completed. Suxamethonium, at a dose of 2 mg kg^{-1} , offers rapid relaxation and optimal intubating conditions; rocuronium at $0.9\text{--}1.2 \text{ mg kg}^{-1}$ may also be used. Etomidate should be employed with caution because of its association with adrenal insufficiency. Adrenal suppression in these critically ill patients may contribute to postoperative hypotension and impair their immune response. Narcotics, benzodiazepines and inhaled agents can potentiate

Table 2. Summary of preoperative optimisation

Oxygen supplementation	High-flow oxygen via a facemask with reservoir bag
Nasogastric tube	Secure airway with tracheal tube if child is obtunded Placed NGT to decompress the distended abdomen Decompression either by low-pressure suction or intermittent aspiration
Fluid resuscitation	Fluid bolus of 20 mL kg^{-1} isotonic crystalloids Reassess child, check CRT and urinary output Fluid bolus repeated if necessary
Correct electrolyte derangement	Correct hypokalaemia (or hyperkalaemia), hyponatraemia, hypochloraemia and metabolic acidosis
Intravenous broad-spectrum antibiotics	Ciprofloxacin/ceftriaxone and metronidazole in areas where strains are multidrug resistant Chloramphenicol, amoxicillin or trimethoprim-sulphamethoxazole in areas where strains are susceptible

hypotension at high doses, but when used in moderation and titrated to effect they can also contribute to a stable anaesthetic.

Maintenance

Maintenance of general anaesthesia can be accomplished with inhalational agents such as isoflurane, sevoflurane or desflurane. In some areas halothane is the only inhalational agent available and may also be used. Deep anaesthesia should be avoided, and special additional attention should be paid to cardiac depression if halothane is employed. The low blood gas solubility coefficient of sevoflurane, desflurane and isoflurane ensures rapid awakening after surgery. These agents can be delivered in a mixture of medical air/oxygen. Nitrous oxide should be avoided.

In patients who are hypotensive, maintenance of anaesthesia may be by intermittent boluses of IV ketamine (0.5 mg kg^{-1}) given according to patient's response or via ketamine infusion ($25\text{--}75 \mu\text{g kg}^{-1} \text{ min}^{-1}$).⁶ Controlled ventilation with monitoring of end-tidal carbon dioxide (if available) is important during surgery. Muscle relaxation will facilitate ventilation and optimise surgical exposure.

A multimodal approach to pain management is encouraged. Simple analgesics such as paracetamol (15 mg kg^{-1} IV) may be given intraoperatively. Opioids such as morphine ($0.05\text{--}0.1 \text{ mg kg}^{-1}$), fentanyl ($1\text{--}2 \mu\text{g kg}^{-1}$ per dose as intermittent boluses) or pentazocine (0.5 mg kg^{-1}) can also be given, but with caution, as they may cause hypotension. Local infiltration of the surgical incision site with bupivacaine can help to decrease the opioid requirement in the postoperative period.

Adequate fluid management is vital in these patients and must take into account preoperative fluid deficits, maintenance requirements and intraoperative losses.⁷ Should a patient remain hypotensive despite adequate volume resuscitation, inotropes or vasopressors, such as dopamine, phenylephrine, noradrenaline or adrenaline, via infusion, should be started and titrated to effect to help maintain haemodynamic stability. It can be helpful to dedicate one IV line to vasoactive agents and maintenance fluids with a second infusion line for replacing fluid deficits and on-going losses and giving bolus injections of drug. Electrolyte derangements are corrected via the maintenance fluid. If a patient is severely acidotic, treatment with sodium bicarbonate should be considered. Blood loss is typically

replaced with non-dextrose-containing crystalloid (e.g. 3 ml of normal saline for each mL of blood lost) or colloid (1 ml of 5% albumin for each mL of blood lost); however, the child's preoperative haematocrit and general status determines when blood transfusion is commenced. Whole blood or packed cells could be transfused and a urinary output of $1\text{--}2 \text{ mL kg}^{-1} \text{ h}^{-1}$ should be aimed at.

Postoperative management

Depending on their condition, these patients should be managed in an intensive care unit (ICU)/high-dependency unit (HDU) as active resuscitation may be required in the postoperative period. If no ICU is available, patients should be moved close to a nurses' station for close observation as deterioration can occur rapidly. In some cases, the patient can be extubated fully awake and continued on high-flow oxygen via a facemask with a reservoir bag. In many other cases, patients may have to be mechanically ventilated postoperatively. The decision to keep the patient intubated should be based on available resources and the status of the patient. Patients should remain intubated if their ventilatory drive is poor, oxygenation is inadequate, ventilation has been difficult (high pressures have been required to maintain adequate volumes) or if resuscitation has been vigorous and involved large amounts of crystalloid, blood, and vasopressors.

These patients should be considered in critical condition and should be monitored closely. Antibiotics should be continued for at least 2 weeks;¹ vasopressors and blood products should be continued postoperatively as needed. Intravenous replacement therapy should be continued with strict monitoring of urinary output. The nasogastric tube should remain in place postoperatively and be placed on suction or gravity until its drainage is minimal. Analgesics such as paracetamol and small doses of IV opioids can be continued as needed for pain. Corticosteroid therapy, which has been found to reduce mortality in the management of typhoid enteritis, has *not* been conclusively proven to improve the outcome in perforated cases. For nourishment, total parenteral nutrition, if available, should be started and continued until oral intake can be tolerated. These patients are at high risk of multiple organ failure; therefore, a comprehensive daily review of each organ system with appropriate management of any derangements is critical in their management.

CONCLUSION

Typhoid perforation is the most serious complication of typhoid fever and children account for a larger proportion of cases. It typically presents with gastrointestinal symptoms though presentation may be atypical in infants or toddlers. Aggressive resuscitation and antibiotic therapy must be commenced before surgical intervention to reduce mortality. Anaesthetic management is of a critically ill child with a full stomach. Postoperative care is key to recovery in these patients and may need to be done in the HDU/ICU.

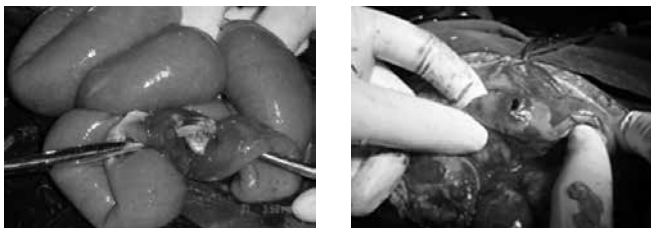

Figure 2. Perforations on the anti-mesenteric border of the terminal ileum (photographs supplied by Professor Emmanuel Ameh, Paediatric surgeon, National Hospital, Abuja, Nigeria).

REFERENCES

1. Ameh EA, Abantanga FA. Surgical complications of typhoid fever. In: Ameh EA, Bickler SW, Lakhoo K, Nwomeh BC, Poenaru D. *Paediatric Surgery: A Comprehensive Text for Africa*. GLOBAL-HELP, Seattle, 2010: 103–10.
2. Nuhu A, Dahwa S, Hamza A. Operative management of typhoid ileal perforation in children. *Afr J Paed Surg* 2010; **7**: 9–13.
3. Ukwenya A, Garba E, Ahmed A. Progress in management of typhoid perforation. *Ann Afr Med* 2011; **10**: 259–65.
4. Kalra SP, Naithani N, Mehta SR, Swamy AJ. Current trends in the management of typhoid fever. *Med J Armed Forces India* 2003; **59**: 130–5.
5. Ugwu BT, Yiltok SJ, Kidmas AT, Opaluwa AS. Typhoid intestinal perforation in North central Nigeria. *West Afr J Med* 2005; **24**: 1–6.
6. Morgan GE Jr, Mikhail MS, Murray MJ. Paediatric anaesthesia. In *Clinical Anaesthesiology*, 4th edn. New York, McGraw Hill; 2008.
7. Wilson CM, Walker IA. Perioperative fluids in children. *Update Anaesth* 2015; **30**: 80–7.