

**Wrist block – landmark technique**

A Girolami, K Russon and A Kocheta

Correspondence: kim.russon@rothgen.nhs.uk

*Originally published as Anaesthesia Tutorial of the Week, 275, 19 November 2012***INTRODUCTION**

A wrist block is the technique of blocking terminal branches of some or all of the six nerves that supply the wrist, hand and fingers. The combination of nerves that need to be blocked depends upon the exact location of surgery. This block can be used to provide regional anaesthesia for a patient undergoing surgery awake or as an analgesic technique to be used in combination with general anaesthesia or brachial plexus block (BPB) using short-acting local anaesthetic (the wrist block will provide prolonged pain relief once the BPB has worn off). It is simple to perform with readily identifiable landmarks, yet remains an underused weapon in the anaesthetist's armamentarium.

**INDICATIONS**

Anaesthesia and/or analgesia is indicated for many surgical procedures on the wrist, hand and fingers, such as wrist arthroscopy, the correction of Dupuytren's contractures, metacarpal or phalangeal osteotomy, arthrodesis of the metacarpophalangeal joints, fixation of fractures in the hand. It is worth noting, however, that, in an awake patient, the duration of surgery may be limited by the patient's ability to tolerate the tourniquet on the upper arm if a wrist block alone is used.

**CONTRAINDICATIONS****Absolute contraindications**

- Patient refusal
- Allergy to local anaesthetic
- Active infection at the site of the block

**Relative contraindications**

- Anti-coagulation or bleeding diathesis

**ANATOMY**

The wrist, hand and fingers are supplied by six nerves:

- the median nerve
- the ulnar nerve
- the dorsal branch of the ulnar nerve
- the radial nerve
- the posterior interosseous nerve
- the anterior interosseous nerve.

All six originate from the brachial plexus and descend into the forearm to supply the distal structures.

**The median nerve**

The median nerve arises from the medial and lateral cords of the brachial plexus and takes fibres from nerve roots C5–C8 and T1 (Figure 1). It has no branches above the elbow but in the forearm supplies the flexor muscles of the forearm (except flexor carpi ulnaris), opponens pollicis, abductor pollicis brevis and the first and second lumbricals. Sensory fibres supply the palmar surface of the radial three and a half fingers and their nailbeds. At the level of the wrist, the median nerve traverses the carpal tunnel and terminates as digital and recurrent branches. The digital branches supply the skin of the lateral three and a half digits and, usually, the lateral two lumbricals. A corresponding area of the palm is innervated by palmar branches, which arise from the median nerve in the distal forearm. The recurrent branch of the median nerve supplies the three thenar muscles. It may be seen that the median nerve must be blocked proximally to the exit of the palmar branches in order to provide complete anaesthesia of the hand (Figures 2 and 3).

**The ulnar nerve**

The terminal branch of the medial cord forms the ulnar nerve, with fibres coming from nerve roots C7–8, T1 (Figure 1). In the forearm, it supplies flexor carpi ulnaris and half of flexor digitorum profundus.

**Summary**

Remember to fully prepare the patient and equipment.

Always aspirate before injecting local anaesthetic.

Ensure that the surgical site is known and all the necessary nerves blocked.

**A Girolami**

Sheffield Teaching Hospitals  
Sheffield  
UK

**K Russon**

Rotherham District General  
Hospital  
Rotherham  
UK

**A Kocheta**

Rotherham District General  
Hospital  
Rotherham  
UK

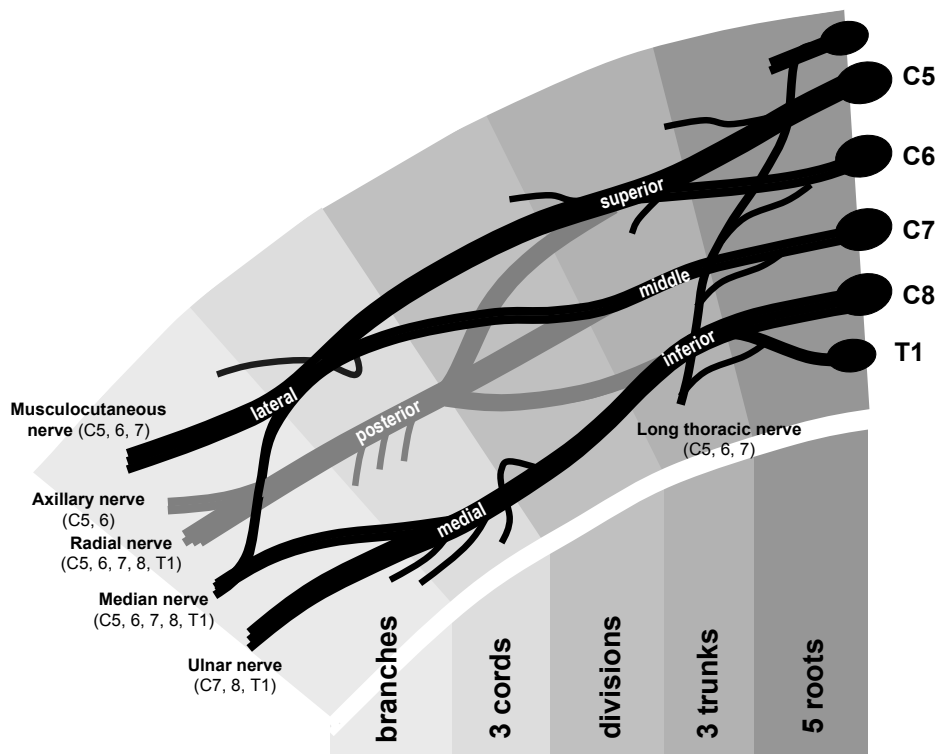


Figure 1. The brachial plexus

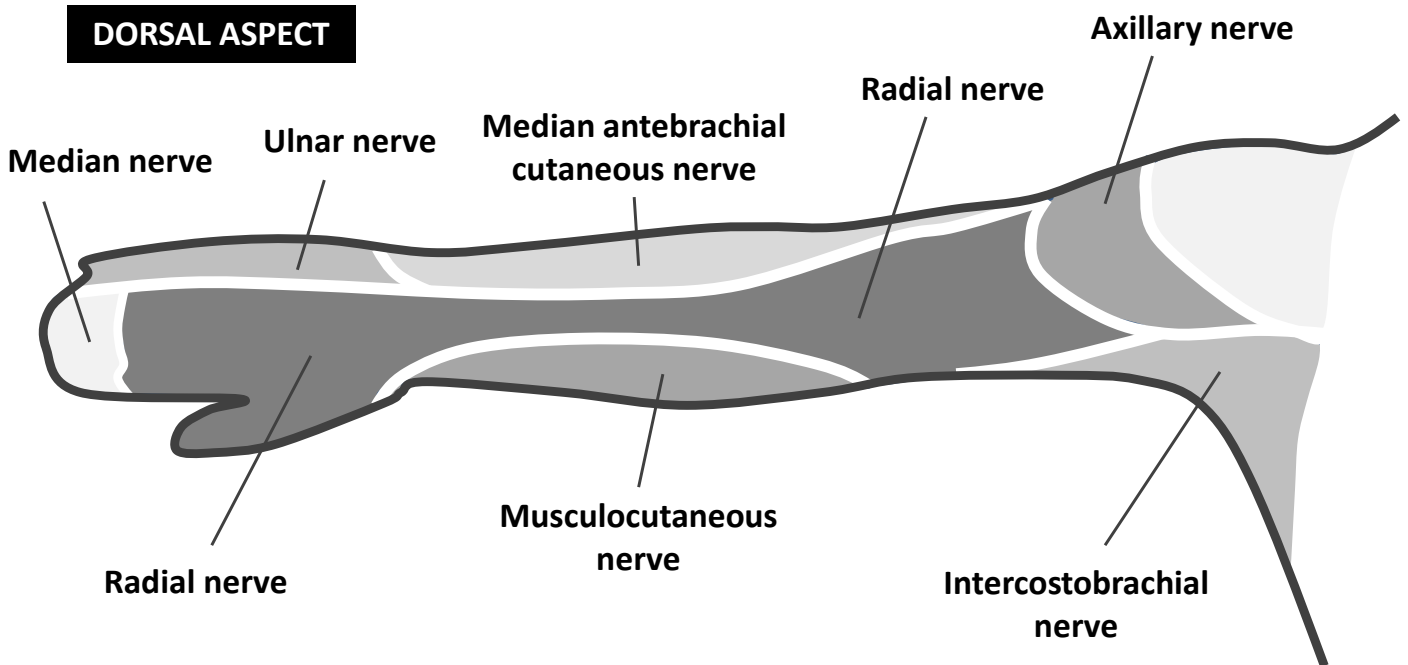


Figure 2. Nerve supply of the arm, palmar surface

In the hand, the deep branch of the ulnar nerve accompanies the deep palmar arch and supplies innervation to the three hypothenar muscles, the medial two lumbricals, all the interossei, and adductor

pollicis. Digital branches provide cutaneous sensation for the medial one and a half fingers. The medial palm is supplied by palmar branches that arise from the ulnar nerve in the distal forearm.

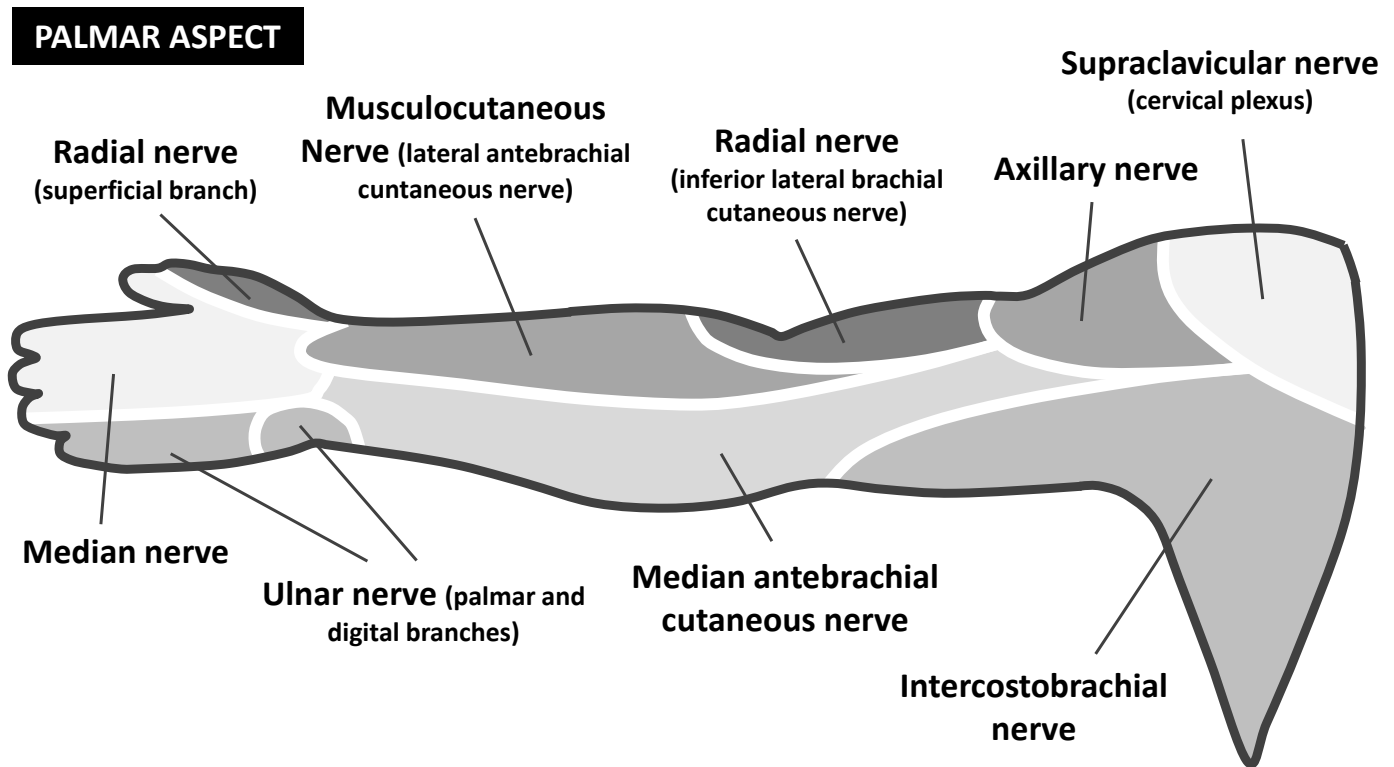


Figure 3. Nerve supply of the arm, dorsal surface

### The dorsal branch of the ulnar nerve

The dorsal, medial side of the hand is supplied by the dorsal branch of the ulnar nerve, which arises proximally to the wrist crease (Figures 2 and 3).

- Tip: Although there may be variability of innervation of the ring and middle fingers, the skin on the anterior surface of the index finger and thumb is always supplied by the median nerve and that of the little finger by the ulnar nerve.

### The radial nerve

The radial nerve is formed from the terminal branch of the posterior cord of the brachial plexus and takes fibres from nerve roots C5–8C and T1 (Figure 1). It travels in the posterior compartment of the upper arm and divides at the level of the elbow into the superficial radial nerve (SRN) and the posterior interosseous nerve (see below). The SRN passes distally on the radial side of the forearm with the radial artery and sensory fibres supply the skin of the lateral aspect of the arm, posterior aspect of the forearm and web space between thumb and index finger (Figures 2 and 3). About 7.5 cm above the wrist, it leaves the artery, pierces the deep fascia to become superficial and divides into two main branches. The external branch, the smaller of the two, supplies the skin of the radial side and base of the thumb.

The internal branch communicates with the posterior branch of the lateral cutaneous nerve. On the back of the hand, it forms an arch with the dorsal cutaneous branch of the ulnar nerve but does not anastomose with it.

### The posterior interosseous nerve

The posterior interosseous nerve (PIN) is the continuation of the deep branch of the radial nerve, taking fibres from nerve roots C7 and C8. It descends on the posterior surface of the interosseous membrane to the back of the wrist, giving motor supply to the extensor muscle bellies of the forearm. Although it is predominantly a motor nerve, it also provides important sensory fibres to the ligaments and various articulations of the wrist.

### The anterior interosseous nerve

The anterior interosseous nerve (AIN) is a branch of the median nerve that accompanies the anterior interosseous artery along the anterior surface of the interosseous membrane of the forearm, in the interval between the flexor pollicis longus and flexor digitorum profundus, ending in the pronator quadratus muscle and wrist joint. Like the PIN, it is a predominantly motor nerve but contributes important sensory fibres to the wrist joints.

## TECHNIQUE

### Preparation and positioning

Fully prepare the equipment and patient, including obtaining informed consent. Also ensure that intravenous access, monitoring and full resuscitation facilities are available. For a more detailed explanation on preparation, see Russon et al.<sup>1</sup>

The patient is in the supine position with the arm abducted. Prepare the skin with antiseptic solution.

### The radial nerve

#### Landmarks (Figure 4)

The SRN runs along the medial aspect of the brachioradialis muscle. It then passes between the tendon of the brachioradialis and radius to pierce the fascia on the dorsal aspect. Just above the styloid process of the radius, it gives digital branches for the dorsal skin of the thumb, index finger and lateral half of the middle finger. Several of its branches pass superficially over the 'anatomical snuff box'.

#### Technique (Figure 4)

The radial nerve is essentially a 'field block' and requires a more extensive infiltration because of its less predictable anatomical location and division into multiple, smaller, cutaneous branches. With the wrist held in slight dorsiflexion, local anaesthetic should be injected subcutaneously, 3 cm proximal to the radial styloid, aiming medially and towards the radial artery but not piercing it. The infiltration is then extended laterally, using up to 5 mL of local anaesthetic.

### The median nerve

#### Landmarks (Figure 5)

The median nerve is located between the tendons of the palmaris longus (PL) – present in approximately 85% of the population – and the flexor carpi radialis (FCR). The PL tendon is usually the more prominent of the two; the median nerve passes just deep and lateral to it.

#### Technique (Figure 5)

The median nerve is blocked by inserting the needle 2.5 cm proximal to the wrist crease between the tendons of palmaris longus and flexor

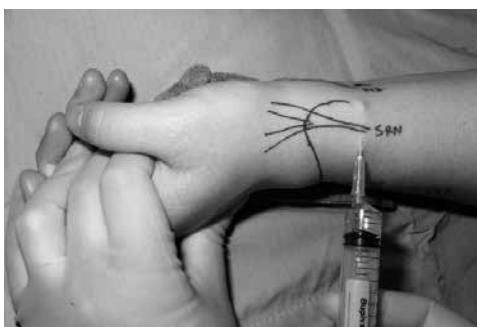

Figure 4. Blocking the superficial branch of the radial nerve (SRN)

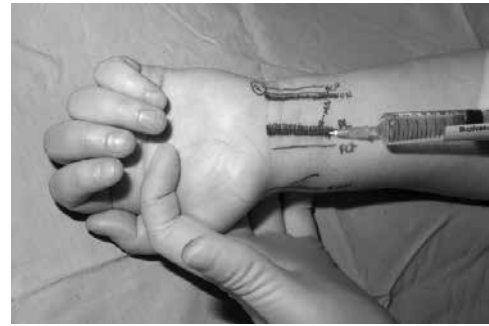


Figure 5. Blocking the median nerve (the needle is inserted between palmaris longus and flexor carpi radialis). FCU, flexor carpi ulnaris; UN, ulnar nerve; PL, palmaris longus; FCR, flexor carpi ulnaris

carpi radialis with the forearm supinated. The needle is inserted until it pierces the deep fascia (3–5 mm), then 3–5 mL of local anaesthetic is injected. Although the piercing of the deep fascia has been described to result in a fascial 'click', it is more reliable to simply insert the needle 3–5 mm as the fascia here is relatively thin and the classical click will not be felt. The median nerve is superficial at this level, proximal to the carpal tunnel, and can easily be penetrated by the needle. Any lancinating symptoms into the fingers felt by the awake patient on needle insertion should prompt withdrawal of the needle because this may indicate that the needle is intraneural. Injection should be easy and with relatively low pressure. Pain in the fingers should not be felt by the awake patient during injection.

### The ulnar nerve

#### Landmarks (Figure 6)

The ulnar nerve passes between the ulnar artery and tendon of the flexor carpi ulnaris (FCU). The tendon of the FCU is superficial to the ulnar nerve, which is the medial to the artery.

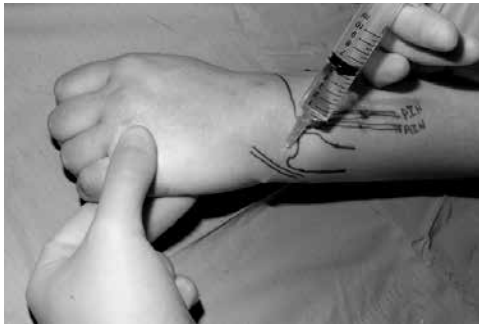
The dorsal cutaneous branch of the ulnar nerve (which must be blocked if anaesthesia to the ulnar aspect of the back of the hand is required) curves around the ulnar aspect of the wrist, 1 cm distal to the ulnar styloid in the mid-axial plane to reach the skin of the back of the hand.

#### Technique (Figures 6 and 7)

The ulnar nerve is anaesthetised by inserting the needle under the

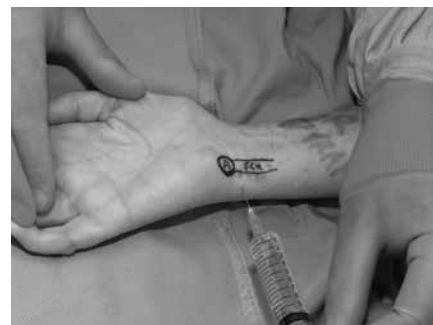

Figure 6. Blocking the ulnar nerve (the needle is inserted under the FCU)



**Figure 7.** Blocking cutaneous branches of the ulnar nerve

tendon of the FCU muscle close to its distal attachment just above the styloid process of the ulna. The needle is advanced 5–10 mm to just past the tendon of the FCU and 3–5 mL of local anaesthetic solution is injected. If blood is aspirated prior to the injection, redirect the needle more superficially and medially as the ulnar artery has been pierced. As with the medial nerve injection, any lancinating symptoms into the fingers felt by the awake patient on needle insertion should prompt redirection.

A subcutaneous injection of 2–3 mL of local anaesthesia just distal to the ulnar styloid with the forearm pronated is also advisable in blocking the cutaneous branches of the ulnar nerve, which often extend to the hypothenar area and the back of the hand.

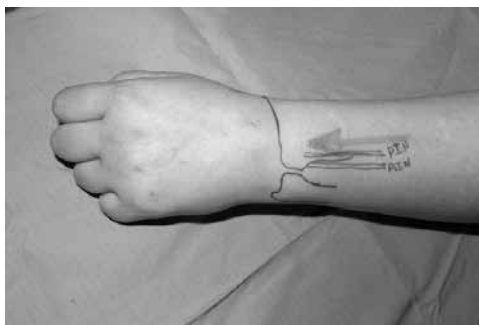### The posterior interosseous nerve

#### Landmarks (Figure 8)

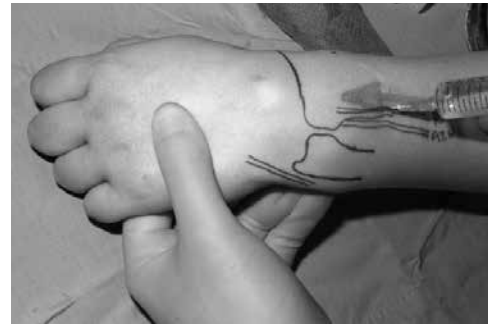The distal articular branch of the PIN lies alongside Lister's tubercle at the level of the wrist, before passing proximally between extensor carpi radialis longus and extensor digitorum.

#### Technique – PIN block (Figure 9)

With the forearm pronated, the PIN is blocked by an injection of local anaesthetic at the palpable ulnar border of the distal radius, 3 cm proximally to the level of the palpable ulnar head. The needle is inserted until it contacts the radial cortex and the anaesthetic is injected onto the periosteum where the nerve lies; 2 mL is adequate.



**Figure 8.** The anatomy of the posterior interosseous nerve (PIN) and the anterior interosseous nerve (AIN)



**Figure 9.** Blocking the PIN

### The anterior interosseous nerve

#### Landmarks (Figure 8)

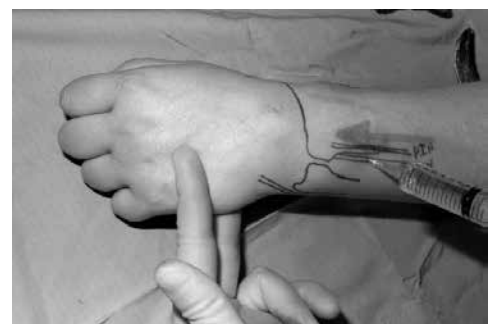
Although the distal articular branch of the AIN is an anterior structure, it is best reached from the posterior aspect of the wrist. Its landmark, therefore, is the radial border of the distal ulna.

#### Technique – AIN block (Figure 10)

Having blocked the PIN, the needle is walked off the ulnar border of the radius and passed between the radius and ulna, through the interosseous membrane, where a 'click' is felt. A further 2 mL of anaesthetic solution is delivered just anterior to the interosseous membrane where the AIN lies.

### LOCAL ANAESTHETIC

The choice of the type and concentration of local anaesthetic for wrist block depends upon the preferences of the individual operator. Whatever the requirements, the total dose should be well within the therapeutic limit/safe dose because the volumes required are not large. To provide anaesthesia and postoperative analgesia, the authors use 15 mL of a mixture of equal parts of 2% lignocaine and 0.5% levobupivacaine, occasionally increasing this to 20 mL. For postoperative analgesia alone, the authors use up to a total of 15 mL of 0.5% levobupivacaine. In order to ensure a consistent 'feel' for the injections, the authors also always use a 10 mL syringe and 23G (blue) needle, whatever the volume used.



**Figure 10.** Blocking the AIN

## COMPLICATIONS

- Block failure – in experienced hands the success rate is 98–100%.
- Bleeding and haematoma.
- Inadvertent vascular injection.
- Infection.
- Nerve damage – this can result from direct trauma, haematoma or high concentrations of local anaesthetic and vasopressor. Incidence ranges from 1 in 2000 to 1 in 50 000.

## WEB LINKS

- The New York School of Regional Anaesthesia – [www.nysora.com](http://www.nysora.com)
- Neuraxiom – [www.neuraxiom.com](http://www.neuraxiom.com)
- RA Education – [www.raeducation.com](http://www.raeducation.com)
- Nerveblocks.net – [www.nerveblocks.net](http://www.nerveblocks.net)

## REFERENCES

1. Russon K, Findley H, Harclerode Z. Peripheral nerve blocks: "Getting started". *Anaesthesia tutorial of the Week* 134; 18 May 2009. Available at [http://www.wfsahq.org/components/com\\_virtual\\_library/media/0149e77a7b0be87704d37dc86d3a0424-8d0233ac1c2a1620b79674aa8a9ea2fe-134-Peripheral-nerve-blocks--getting-started.pdf](http://www.wfsahq.org/components/com_virtual_library/media/0149e77a7b0be87704d37dc86d3a0424-8d0233ac1c2a1620b79674aa8a9ea2fe-134-Peripheral-nerve-blocks--getting-started.pdf)

## FURTHER READING

- Ferreres A, Foucher G, Suso S. Extensive denervation of the wrist. *Techn Hand Up Extrem Surg* 2002; **6**(1): 36–41.

## ACKNOWLEDGEMENTS

Photographs from personal archive of Mr A. Kocheta. Reproduced with permission. Figures 2 and 3 courtesy of Edwina Kelly. Reproduced with permission.